

# Diagnostic Lumbosacral Segmental Nerve Blocks With Local Anesthetics: A Prospective Double-Blind Study on the Variability and Interpretation of Segmental Effects

André P. Wolff, M.D., Gerbrand J. Groen, M.D., Ph.D.,  
and Ben J.P. Crul, M.D., Ph.D.

**Background and Objectives:** Selective spinal nerve infiltration blocks are used diagnostically in patients with chronic low back pain radiating into the leg. Generally, a segmental nerve block is considered successful if the pain is reduced substantially. Hypesthesia and elicited paresthesias coinciding with the presumed segmental level are used as controls. The interpretation depends on a standard dermatomal map. However, it is not clear if this interpretation is reliable enough, because standard dermatomal maps do not show the overlap of neighboring dermatomes. The goal of the present study is to establish if dissimilarities exist between areas of hypesthesia, spontaneous pain reported by the patient, pain reduction by local anesthetics, and paresthesias elicited by sensory electrostimulation. A secondary goal is to determine to what extent the interpretation is improved when the overlaps of neighboring dermatomes are taken into account.

**Methods:** Patients suffering from chronic low back pain with pain radiating into the leg underwent lumbosacral segmental nerve root blocks at subsequent levels on separate days. Lidocaine (2%, 0.5 mL) mixed with radiopaque fluid (0.25 mL) was injected after verifying the target location using sensory and motor electrostimulation. Sensory changes (pinprick method), paresthesias (reported by the patient), and pain reduction (Numeric Rating Scale) were reported. Hypesthesia and paresthesias were registered in a standard dermatomal map and in an adapted map which included overlap of neighboring dermatomes. The relationships between spinal level of injection, extent of hypesthesia, location of paresthesias, and corresponding dermatome were assessed quantitatively. Comparison of the results between both dermatomal maps was done by paired *t*-tests.

**Results:** After inclusion, data were processed for 40 segmental nerve blocks (L2-S1) performed in 29 patients. Pain reduction was achieved in 43%. Hypesthetic areas showed a large variability in size and location, and also in comparison to paresthesias. Mean hypesthetic area amounted  $2.7 \pm 1.4$  ( $\pm$  SD; range, 0 to 6; standard map) and  $3.6 \pm 1.8$  (0 to 6; adapted map;  $P < .001$ ) dermatomes. In these cases, hypesthesia in the corresponding dermatome was found in 80% (standard map) and 88% of the cases (adapted map, not significant). Paresthesias occurring in the corresponding dermatome were found in 80% (standard map) compared with 98% (adapted map,  $P < .001$ ). In 85% (standard map) and 88% (adapted map), spontaneous pain was present in the dermatome corresponding to the level of local anesthetic injection. In 55% (standard map) versus 75% (adapted map,  $P < .005$ ), a combination of spontaneous pain, hypesthesia, and paresthesias was found in the corresponding dermatome.

**Conclusions:** Hypesthetic areas determined after lumbosacral segmental nerve blocks show a large variability in size and location compared with elicited paresthesias. Confirmation of an adequately performed segmental nerve block, determined by coexistence of hypesthesia, elicited paresthesias and pain in the presumed dermatome, is more reliable when the overlap of neighboring dermatomes is taken into account. *Reg Anesth Pain Med* 2001;26:147-155.

**Key Words:** Segmental nerve blocks, Diagnostic, Lumbosacral, Chronic low back pain, Invasive pain treatment, Dermatomal map.

---

From the Pain Centre (A.P.W.), Department of Anaesthesiology, Bernhoven Hospital, Oss, The Netherlands; the Division of Perioperative Medicine, Anaesthesiology and Pain Treatment (G.J.G., A.P.W.), University Medical Centre Utrecht, Utrecht, The Netherlands; and the Pain Centre (A.P.W., B.J.P.C.), Institute for Anaesthesiology, University Hospital Nijmegen, Nijmegen, The Netherlands.

Accepted for publication November 6, 2000.

Reprint requests: André P. Wolff, M.D., Regional Pain Centre, Department of Anaesthesiology, Bernhoven Hospital, PO Box 10, 5340 BE Oss, The Netherlands. E-mail: awolff@planet.nl or a.wolff@bernhoven.nl

© 2001 by the American Society of Regional Anesthesia and Pain Medicine.

1098-7339/01/2602-0010\$35.00/0

doi:10.1053/rapm.2001.21436

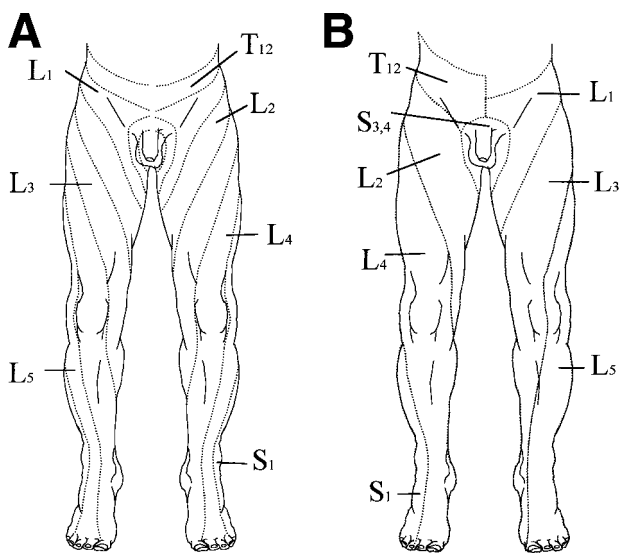
Selective segmental nerve blocks are applied for diagnostic purposes in patients with chronic pain to differentiate the segmental level of pain.<sup>1-5</sup> If the pain lasts more than 6 months without improvement despite conservative treatment, and if a selective segmental block has led to temporary pain relief, there may be an indication for invasive symptomatic pain treatment.<sup>1</sup> To assess the quality of a diagnostic segmental block, the presence and extent of temporary motor deficit, dermatomal hypesthesia, and elicited paresthesias are useful criteria.

Location and size of hypesthetic regions and intensity of paresthesias are generally evaluated by using a standard dermatomal map. In the past, different attempts have been made to develop a human dermatomal map. Maps were designed based on the location of skin eruptions in herpes zoster,<sup>6</sup> innervation territories of peripheral branches of lumbosacral and brachial plexuses by meticulous anatomical dissection of 1 human,<sup>7</sup> and by experimental animal work on monkeys.<sup>8</sup> Sherrington<sup>8</sup> determined dermatomal areas by using the isolation method and checking the areas of remaining sensibility. Sherrington used the "remaining sensibility method" or "isolation method" in monkeys, by cutting a continuous number of dorsal roots and leaving intact the most middle root. In this way, he created for nearly all spinal nerves areas with intact sensibility surrounded by areas in which sensibility was absent. Thus, he proved an overlap in sensory nerve supply by consecutive nerve roots and showed that most cutaneous loci were innervated by 2 or 3 dorsal roots. Larger dermatomal areas were found with considerable overlap between neighboring dermatomes. Keegan and Garrett<sup>9</sup> used local anesthesia of the dorsal root ganglia in healthy subjects. Hansen and Schliack<sup>10</sup> made use of the above-mentioned studies and synthesized the data with personal clinical observations into a renewed human dermatomal map. Their map was again modified by Buckhøj (an artist) and is currently used as a standard in many pain clinics and anesthesia practices. The maps of the dermatomes in humans worked out by different methods are not concordant in all respects, but the main patterns are identical.<sup>11</sup>

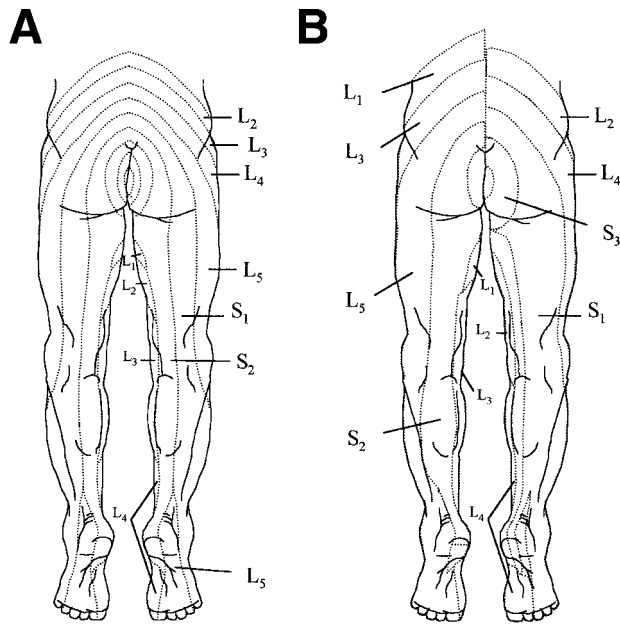
Diagnostic segmental blocks performed at the same level do not always produce equal dermal extension of sensory changes<sup>12</sup> and may provide false-positive results.<sup>13</sup> North et al.<sup>13</sup> compared the temporary pain-relieving effects of lumbosacral nerve root blocks, sciatic nerve blocks, medial branch posterior primary ramus blocks, and subcutaneous injections in patients with sciatica and diagnosed root entrapment. The first 3 blocks produced temporary relief in the majority of patients

despite the fact that they were distal to the entrapped nerve. The study hypothesis that false-positive results are common and specificity is low was confirmed. Much of the exact mechanism of diagnostic segmental nerve blocks still needs to be elucidated.

In the present study the extension of sensory changes after single segmental lumbosacral nerve blocks was assessed by the pinprick method and fitted in a standard dermatomal map (Buckhøj; Astra-Zeneca, Södertälje, Sweden; Figs 1A and 2A) frequently used in local and regional anesthesia. Sherrington<sup>8</sup> and Foerster<sup>14</sup> showed that neighboring dermatomes overlap to a large extent. This means that the full extent of each dermatome is larger than depicted in the vast majority of complete dermatomal maps. Foerster<sup>14</sup> defined the total extent of a dermatome as "one dermatome to which both half neighboring dermatomes were added." However, in Foerster's dermatomal map, not all dermatomes are presented as a continuum from proximal to the periphery. Therefore, Keegan and Garrett<sup>9</sup> proposed a dermatomal chart representing dermatomes extending without interruption from the dorsal midline to their termination. However, Keegan and Garrett's chart represents only the core of the dermatomes, described as "areas of primary hyposensitivity." As a result, we modified the frequently used standard map of Buckhøj by adding to the original dermatome both halves of the 2 neighboring dermatomes. Thus, larger dermatomes were obtained (adapted map; see Figs 1B and 2B). The findings were quantitatively fitted in both maps and compared with each other.



**Fig 1.** Standard dermatomal map (A) versus adapted dermatomal map (B), anterior.



**Fig 2.** Standard dermatomal map (A) versus adapted dermatomal map (B), posterior.

Although spinal segmental test blocks are performed to obtain more insight into pain patterns, the questions in this study were limited to the following issues: (1) How often does a single segmental nerve block lead to hypesthesia in the corresponding dermatome? (2) How often does electrical nerve stimulation of a single segmental nerve elicit paresthesias in the corresponding dermatome? (3) How often do areas of spontaneous pain, hypesthesia, and elicited paresthesia coincide within the corresponding dermatome?

The results will be compared between the standard and adapted dermatomal maps.

### Patients and Methods

Patients suffering from unilateral chronic low back pain radiating to the leg, in which noninvasive therapy was excluded, were referred for symptomatic invasive pain treatment. All patients were examined extensively, including by computed tomography (CT), magnetic resonance imaging (MRI), and electromyograph (EMG), and diagnosed as “radicular syndrome without neurological deficit” by a neurologist or an orthopedic surgeon. Patients were recruited in accordance with the rules of the Declaration of Helsinki and the study was approved by the Hospital Ethics Committee. Written informed consent was obtained from each patient. All patients were over 18 years of age.

Exclusion criteria were the following: availability of noninvasive therapy, known hypersensitivity to amino-amide-type local anesthetics or iodide,

presence of coagulopathy, or mental disorders. In the study period, 38 consecutive patients with radiating pain in the lower limbs were considered for diagnostic lumbosacral segmental nerve blocks. After obtaining written, informed consent, 29 patients were enrolled the study. They were scheduled for 3 test blocks with local anesthetics—1 block at the segmental nerve corresponding with the most painful dermatome, and the remaining 2 at the super- and subjacent levels. Finally, during the study period, 29 patients underwent 42 diagnostic segmental nerve blocks at lumbosacral levels according to the experimental protocol.

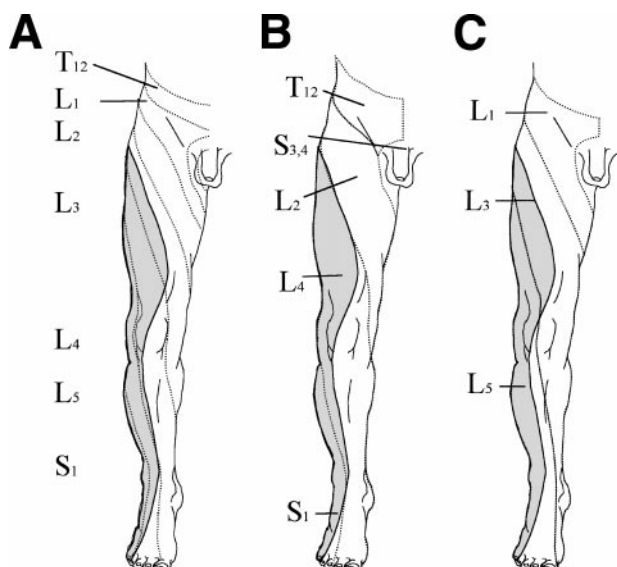
The blocks were performed by 3 anesthesiologists specializing in invasive pain treatment. A research fellow, unfamiliar with the exact level of the executed block, performed assessment of the blocks.

### Technique

The patient was positioned prone. Fluoroscopy was executed in an antero-posterior and lateral direction. Under fluoroscopic guidance, the insertion site of the needle was marked on the skin by a skin marker. After subcutaneous injection with 1 mL of lidocaine 1.5%, a 10-cm isolated needle was inserted into the intervertebral foramen (23-gauge, Top-XE; Top Corp, Tokyo, Japan).

To confirm the position of the needle, an electrical current generated by a radio frequency pulse and lesion generator system (model RFG-3B; Radionics, Burlington, MA) was applied, stimulating the segmental nerve. Paresthesias were evoked by stimulation with a frequency of 50 Hz and muscular contractions by stimulating at 2 Hz. The paresthesias elicited in the patient were registered by the anesthesiologist in an “empty” dermatomal map. The anesthesiologist recorded the locations of these sensations as expressed by the patient as well as the presence of muscular contractions manifest during electrical stimulation. Thereafter, 0.3 mL contrast medium (Omnipaque Nycomed Ireland, LTD, Cork, Ireland) was injected through the needle to visualize the segmental nerve. Radiographs were taken for documentation. Then a mixture of 0.5 mL lidocaine 2% (Astra Pain Control AB, Södertälje, Sweden) and 0.25 mL of contrast dye was injected. In case of epidural or abnormal spread, the data were excluded from further analysis.

The “blind” investigator examined the patients twice: 30 minutes before and between 15 and 30 minutes after the injection. Sensory tests were performed in the affected limb from distal to proximal in annular shapes at 10-cm distances by pinprick (hypo, 825044A, 27-gauge; MPL Technologies Inc, Franklin Park, IL). The other limb was used as a



**Fig 3.** Hypesthetic area (case no. 5) after a segmental nerve block of L4, projected on a standard map (A) and on adapted dermatomal maps (B and C).

reference. The areas with sensory changes were fitted in the standard and the adapted dermatomal maps (Fig 1). The dermatomal map was provided with a grid with a resolution of 1 mm<sup>2</sup> to quantify the surface of the hypesthetic areas. Hypesthetic areas were marked. The number of marked squares per dermatome, as well as the total number of marked squares, were counted. Thus, the relative sizes of hypesthetic areas within affected dermatomes in comparison to the total hypesthetic areas were calculated. This was done for both standard and adapted maps.

With the standard map, each affected locus in a hypesthetic area lies in only 1 dermatome. These dermatomes are only neighboring. Using the adapted map, each affected locus is, by definition, lying in more than 1 dermatome because the larger dermatomes on the adapted map do overlap. Therefore, the mean hypesthetic area will be larger using the adapted map. For example, when a small coin-sized area is affected at the lateral side of the knee with a total surface of "X," it can only be counted once in dermatome L5 in the standard map. In the adapted map, the affected area is found within dermatome L5, but also in L4 (see Figs 1 or 3). When we calculate the total surface of the hypesthetic area using the standard map we only can count "X," but using the adapted map in this case we can count "2X."

To determine which areas were hypesthetic in the majority of patients, intensity maps were produced from superimposed data of all cases.

The following data were processed: the der-

matome(s) in which the patient experienced the pain, the pain score before and after the segmental nerve block (on a 10-point Numeric Rating Scale [NRS], 0 = no pain, 10 = unbearable pain), the spinal level of the blocked nerve, the voltages at which paresthesias and muscle contractions were perceived during electrical stimulation (mean  $\pm$  SD), and the dermal projection of paresthesias. A decrease of at least 2 points on the NRS was considered to be clinically significant.

To compare the effects related to the level of spinal nerve infiltration, hypesthesia, and paresthesias between standard and the adapted dermatomal maps, the paired *t*-test was used with a confidence interval of 95%.

## Results

Forty-two segmental nerve blocks were performed in 29 patients. Data of 2 block procedures were excluded from further analysis because of epidural spread. An L2 nerve block was performed in 6 cases, an L3 in 1, an L4 in 8, an L5 in 14, and an S1 in 11 cases. In all cases, the number of the vertebrae from C1 to the treated level was normal. For demographic data, see Table 1. In Fig 3, a hypesthetic area, developed in a case after a segmental nerve block of L4, is presented in a standard map (3A) and in adapted dermatomal maps (3B and 3C). Superimposition of hypesthetic areas per level of segmental nerve block shows a large overlap in all cases, as shown for levels L5 and S1 in intensity maps (Figs 4 and 5).

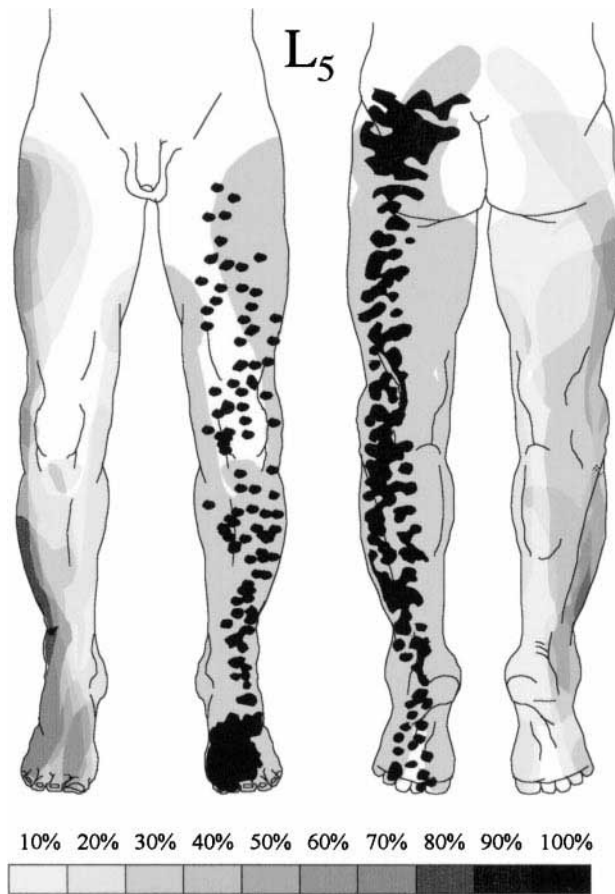
Hypesthesia locations with the highest intensity are found at the anterior thigh (L2, 30%), at the anterolateral side of the knee (L4, 40%), at the lateral caudal half of the lower leg and lateral ankle (L5, 80%), and at the dorsolateral thigh, lateral ankle, and lateral side of the foot (S1, 60%).

Elicited paresthesias are found in the anterior side of the upper leg, knee, and upper part of the lower leg (L4), over the buttock along the dorsal side of the thigh and lateral side of the lower leg to the great toe (L5, Fig 4), and from the buttock over the dorsal side of upper and lower leg to the lateral side of the foot to the fifth digit (S1, Fig 5).

Comparisons were made between the presence of

**Table 1.** Demographic Data in Patients With Pain in the Lower Limbs Undergoing Segmental Nerve Blocks

	No.
Patients	29
Sex: F/M	12/17
Age (SD, range)	49.3 (11.0, 29-77)
Blocks	40



**Fig 4.** Intensity map of L<sub>5</sub> areas of hypalgesia (gray tones in right legs) and paresthesias (black dots in left legs; gray area represents total area of paresthesia) in 14 patients. Areas of hypesthesia and paresthesia of all 14 patients have been superimposed. The gray tones correspond with the intensity scale that describes the percentage of patients in which the areas overlapped each other. The darkest areas represent sites that were found hypesthetic in the largest number of patients. For paresthesia it is depicted as more black dots at a certain spot.

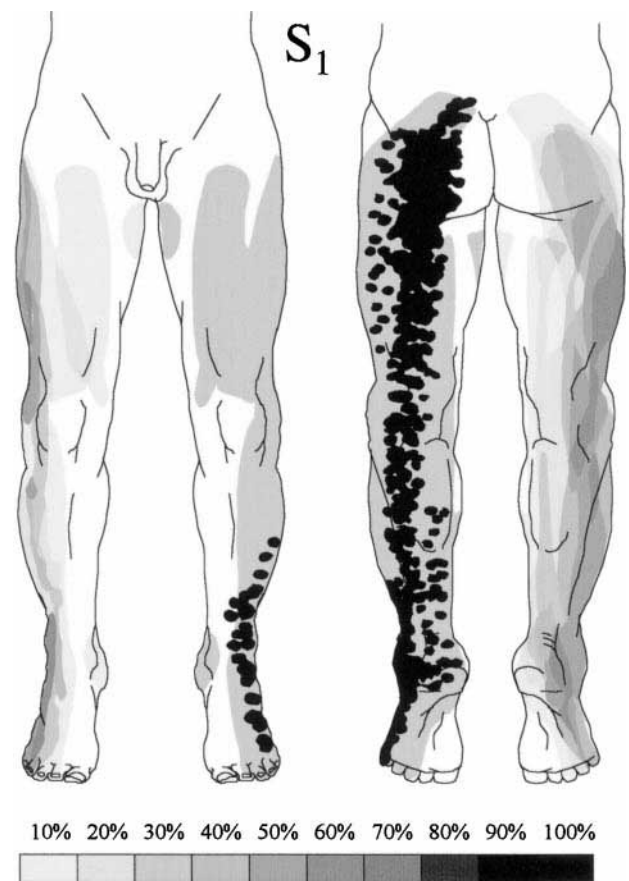
spontaneous pain, hypesthesia, paresthesia, and pain reduction in corresponding dermatomes in standard and adapted dermatomal maps (Fig 6). In all but 1 (i.e., frequency of hypesthetic area), the frequency of signs and symptoms located in the corresponding dermatome is significantly higher in the adapted dermatomal map.

After single segmental nerve blocks, hypesthesia was found in 34 cases (85%), but was not detected in 6 cases (15%). The hypesthetic surface areas as recorded on the dermatomal maps (both standard and adapted) varied from 0 to 1,244 mm<sup>2</sup> (mean  $\pm$  SD, 537  $\pm$  357 mm<sup>2</sup>; Fig 7). In 40 cases, areas of hypesthesia were recorded within the boundaries of a total of 106 (standard map) and 145 dermatomes (adapted map). Hypesthetic areas extended over

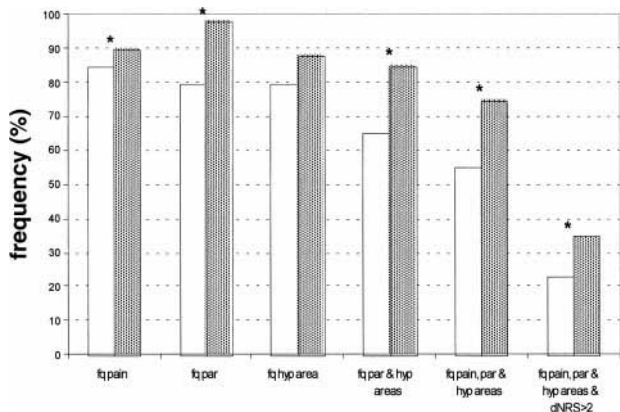
2.7  $\pm$  1.4 dermatomes (mean  $\pm$  SD; range, 0 to 6; standard map) and 3.6  $\pm$  1.8 dermatomes (mean  $\pm$  SD; range, 0 to 6; adapted map;  $P < .001$ , paired  $t$ -test).

Hypesthesia occurred in the corresponding dermatome in 32 cases (standard map) and 35 cases (adapted map; not significant [NS], paired  $t$ -test). The mean hypesthetic surface area in the corresponding dermatome (as percentage of the mean total hypesthetic area) was 26% (standard map) versus 52% (adapted map;  $P < .01$ , paired  $t$ -test). Using the standard map, at least 50% of the total hypesthetic area was found within the corresponding dermatome in only 6 cases (15%), but in 23 cases (58%;  $P < .001$ , paired  $t$ -test) for the adapted map.

The mean measured voltage necessary to elicit



**Fig 5.** Intensity map of S<sub>1</sub> areas of hypalgesia (gray tones in right legs) and paresthesias (black dots in left legs; gray area represents total area of paresthesia) in 11 patients. Areas of hypesthesia and paresthesia of all 11 patients have been superimposed. The gray tones correspond with the intensity scale that describes the percentage of patients in which the areas overlapped each other. The darkest areas represent sites that were found hypesthetic in the largest number of patients. For paresthesia it is depicted as more black dots at a certain spot.



**Fig 6.** Relationships between frequency of presence of spontaneous pain, elicited paresthesias (par), hypesthesia (hyp), and decrease in pain (dNRS) in corresponding dermatomes of standard (□) versus adapted (▨) dermatomal maps in 40 cases undergoing lumbosacral segmental nerve blocks. \* $P < .05$ .

paresthesias was  $0.8 \pm 0.6$  V (SD), range, 0.1 to 2.0 V. Muscle contractions were elicited at a mean voltage of  $1.4 \pm 1.1$  V (SD), range, 0.15 to 4.0 V. After electrical stimulation, in 32 cases (80%, standard map) versus 39 cases (98%, adapted map;  $P < .01$ , paired  $t$ -test), paresthesias were experienced in dermatomes corresponding to the level of the segmental nerve block. In the remainder of cases, paresthesias were perceived in dermatomes not corresponding to the level of the stimulated segmental nerve. Areas with paresthesias were generally of limited size and showed a more bandlike pattern in comparison with hypesthetic areas. In 26 cases (65%, standard map) versus 34 cases (85%, adapted map;  $P < .005$ , paired  $t$ -test), hypesthesia and paresthesias were recorded in the corresponding dermatome.

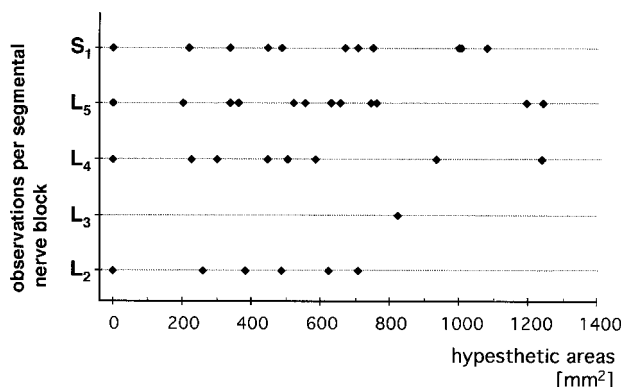
In most cases, spontaneous pain was located in an area exceeding the boundaries of at least 2 dermatomes with a mean of  $2.4 \pm 1.3$  dermatomes (mean  $\pm$  SD; range, 1 to 6; total 93; standard map) versus  $3.4 \pm 1$  dermatomes (mean  $\pm$  SD; range, 2 to 6; total 131; adapted map;  $P < .001$ , paired  $t$ -test). Using the standard dermatomal map, pain was present in only 1 dermatome in 11 cases. Using the adapted map, in 5 cases pain was present in just 2 dermatomes. In 34 and 35 cases, pain was present in the dermatome corresponding to the treated spinal nerve. In 17 cases, (43%, both maps) pain was reduced significantly, of which in 14 (standard map) and 15 cases (adapted map) the level of segmental nerve block corresponded with the painful dermatomal area. In 3 and 2 cases, the segmental nerve block was performed at a spinal level not represented in the painful area. In 55% (standard

map) versus 75% (adapted map,  $P < .005$ ), the combination of spontaneous pain, hypesthesia, and paresthesias was found in the corresponding dermatome.

**Discussion**

The mean hypesthetic surface area in the corresponding dermatome with the standard maps was half (26%) of the mean area found using the adapted dermatomal map (52%;  $P < .01$ , paired  $t$ -test). This is a direct consequence of the characteristics of the maps: each locus on the standard map is always represented twice on the adapted map. It is, nevertheless, remarkable that on both maps the dermatome representing the greatest part of hypesthesia generally is not the dermatome corresponding to the blocked segmental nerve. This was only found in 11 (standard map) and 12 (adapted map) cases of the 40 test blocks.

In most cases using the standard and adapted dermatomal maps, hypesthesia after single segmental nerve block was found in at least 2 dermatomes (range, 1 to 6). The mean area of hypesthesia interpreted in the standard map differed with statistical significance from the adapted map areas ( $2.7 \pm 1.4$  dermatomes, standard  $v$   $3.6 \pm 1.8$  dermatomes, adapted map;  $P < .001$ , paired  $t$ -test). In 6 cases, no hypesthesia was found. Therefore, single segmental nerve blocks, as applied in the present study, seem to have a limited selectivity with regard to sensory changes. In the cases where no hypesthesia was found, the pinprick method might have been too insensitive to detect hypesthesia, or hypesthesia did not develop at all, or the effect was concealed by overlap by neighboring dermatomes.



**Fig 7.** The hypesthetic surface areas per segmental nerve block (L2, 6 cases; L3, 1 case; L4, 8 cases; L5, 14 cases; and S1, 11 cases) as recorded on the dermatomal maps, both standard and adapted, depicted in mm<sup>2</sup>. In 6 cases no hypesthesia occurred: L2, 1 case; L4, 1 case; L5, 3 cases; S1, 1 case.

The finding of hypesthetic areas exceeding 1 dermatome may seem surprising, but it is actually a normal representation of the extensive receptive fields of 1 segmental nerve. In this way, the peripheral nerve branches of 1 segmental nerve intermingle with similar branches of the sub- and suprajacent segmental nerves, as already described by Bolk.<sup>7</sup> Sherrington<sup>8,15</sup> also described an overlap in skin innervation and showed that most cutaneous loci were supplied by 2 or 3 consecutive posterior roots. This was corroborated in dogs by Fletcher and Kitchell.<sup>16</sup> Foerster<sup>14</sup> confirmed overlap in human dermatomes using 3 different methods: Sherrington's "remaining sensibility method"; the Strickers and Bayliss method<sup>14</sup>—dermatomal vasodilatation by faradic stimulation of the distal part of a divided posterior nerve root; and finally his own "constructive method"—when a series of contiguous roots is divided, the superior border of the resulting anesthesia represents the inferior border of the dermatome corresponding to the next higher intact root, while the inferior border of the anesthetic area represents the superior border of the next lower dermatome. Finally, overlap of innervation was shown in various animals by several other investigators.<sup>17-23</sup>

The extent of hypesthesia over more than 3 dermatomes may be related to undetected epidural or distal spread of local anesthetics during injection, although this was controlled visually. Epidural spread was only seen in 2 cases that were excluded. A second explanation might be the way in which the adapted map was constructed. We assumed an overlap by 2 halves of neighboring dermatomes. However, a more extensive overlap may exist, as, for example, suggested by Fletcher and Kitchell.<sup>16</sup>

Other factors may also contribute to inaccuracies in the findings with respect to hypesthesia. The conversion from skin to map may lead to a shift. The pinprick method is rather insensitive in assessing the extent of the vital sensory changes. It cannot discriminate between subtle differences with respect to lower and higher tactile thresholds.<sup>16</sup> More precise outcomes can possibly be obtained when applying a modified Von Frey-hair test: e.g., Semmes-Weinstein.<sup>24,25</sup>

Nitta et al.<sup>12</sup> studied spinal nerve blocks by applying lidocaine to the spinal nerves L4, L5, and S1 and tested the sensory system by using the writing brush method. They found distinctive regions including the medial side of the lower leg (L4), the posterior side of the great toe (L5), and the fifth digit of the foot (S1). In 43%, 44%, and 92% (L4-S1), respectively, Nitta et al.<sup>12</sup> found bandlike zones from the posterior midline of the trunk to the periphery formed by regions of sensory impairment.

Their findings are in agreement with the theory of Keegan and Garrett<sup>9</sup> with respect to the bandlike dermatomes. In the present study, the same regions were found included in the hypesthetic areas. However, the highest frequency of hypesthesia were found in the lateral thigh and anterolateral side of the knee (L4), at the lateral caudal half of the lower leg and lateral ankle (L5), and at the dorsolateral thigh, lateral ankle, and lateral side of the foot (S1). Only the latter is in agreement with the findings of Nitta et al.<sup>12</sup> Furthermore, we discerned bandlike hypesthetic zones in many individual cases, but after superimposition of all total hypesthetic areas we found quite extensive regions, as depicted in the intensity maps. However, regions with higher intensities tend to form bandlike zones as well. Nitta et al.<sup>12</sup> present bandlike zones but do not give any description of superimposition of the total hypesthetic areas. Furthermore, they used lidocaine at a volume and concentration twice as high as that used in our study and did not describe any control of spread of their study drug after injection.

In contrast, superimposed areas with paresthesias were generally of limited size and showed a more bandlike pattern in comparison with hypesthetic areas. The discrepancy between the occurrence of paresthesias and hypesthesia in the corresponding dermatome can possibly be explained by the more local effect of electrostimulation on the neural tissue. The effect of the injected local anesthetic also depends on many pharmacokinetic and pharmacodynamic factors. Although the methodology differs, our findings of regions with paresthesias seem to fit with those of Nitta et al.<sup>12</sup> for L4, L5, and S1. Also, the locations representing the highest density of superimposed paresthesias correlate quite well for L5 and S1, with the highest incidence of hypesthesia for L5 and S1 in the study of Nitta et al. Only paresthesias after neurostimulation at L4 remain more anterior in the lower leg in our patients.

The frequency of hypesthesia and paresthesias in the corresponding dermatomes (Fig 6) was equal for the standard map (80%). For the adapted map these figures tend to be somewhat better: 98% (paresthesias) versus 88% (hypesthesia;  $P = .1$ , paired  $t$ -test). Comparison between both maps for frequency of paresthesias in the corresponding dermatome shows a significantly higher score for the adapted map (98%  $v$  80%;  $P < .01$ , paired  $t$ -test), stressing the significance of including neighboring dermatomes in dermatomal maps.

Whereas this study was primarily directed toward the interpretation of the sensory effects caused by segmental nerve blocks, some remarks can be made with respect to pain. Using the adapted map, pain was present in 1 dermatome (mean  $\pm$  SD: 2.4  $\pm$

1.3) in only 11 cases, while using the adapted map pain was always present in at least 2 dermatomes (mean  $\pm$  SD:  $3.4 \pm 1.0$ ). The extensive areas representing pain in most cases, and the multisegmental innervation pattern (each dermal locus is supplied from 3 adjacent spinal levels), reemphasize the need to perform diagnostic segmental nerve blocks at more than 1 level to obtain insight into the effects on pain. However, after blocking 40 single segmental nerves, in 6 cases no sensory changes could be demonstrated. In 2 of these cases, a significant decrease in pain was experienced: in one, the segmental nerve block was performed at a level represented in the pain area, and in the other case the block was performed at an adjacent level. In both cases there was no difference between the standard and the adapted map. In the 4 remaining cases pain did not diminish, while the block was performed at a spinal level corresponding to the painful area. These phenomena underline the complexity of pain transmission.

Although all patients had been diagnosed as "radicular syndrome without neurological deficit," this does not mean that all patients should have a pathophysiological process comprising the segmental nerve. Other sources of pain might also be considered.<sup>1,13</sup> However, the mechanism and interpretation of the effects of diagnostic lumbosacral segmental nerve blocks was the primary issue of the present study, and not pain or pain reduction. Questions remaining are the influence, type, and concentration of local anesthetic drug, the minimal volume needed, and consequences on extension, duration, and quality of block of mixing a local anesthetic agent with radio-opaque fluid. Also, the position of the tip of the needle is critical for the spread of the study solution. Particularly, the position of the tip of the needle relative to the foramen is of paramount importance in obtaining a selective spinal nerve (and ganglion) block.<sup>1</sup> Placing the needle tip too medially can result in epidural spread. A refinement of the projection procedure in computing the area of hypesthesia from skin to paper needs further study. Furthermore, we are aware of the rather small number of cases included in this study.

Nevertheless, the results contribute to a further elucidation of the mechanism and role of the segmental nerve blocks. With respect to the use of dermatomal maps, the frequency of hypesthesia and paresthesias in the corresponding dermatome are significantly higher in the adapted map compared with the standard map. As stated earlier,<sup>11</sup> dermatomes should not be considered as static, but need to be regarded as neurophysiological entities. In our opinion, a dermatomal map in which neighboring dermatomes are included is more concor-

dant with this principle, as shown by the significantly higher scores of the combined presence of spontaneous pain, hypesthesia, and paresthesias in corresponding dermatomes.

## Conclusion

After segmental nerve block, a large variability in size and location of hypesthetic areas is found that is much more variable than considered until now; hypesthesia shows also more variability compared with elicited paresthesias. This seems to be in accord with the overlapping innervation pattern of dermatomes and reemphasizes the fact that dermatomes are more extensive than depicted in standard dermatomal maps. Confirmation of an adequately performed segmental nerve block, as determined by coexistence of hypesthesia, elicited paresthesias, and pain in the presumed dermatome, is more reliable when the overlap of neighboring dermatomes is taken into account.

Further studies are necessary to enhance the technique of the segmental nerve block, to find the optimal mixture of drugs used in the spinal nerve block, and to elucidate the clinical significance of the adapted map.

## Acknowledgment

The authors thank G. Braak, C. Slegers, and M. Bijman for their special contributions.

## References

1. Stolker RJ, Vervest ACM, Groen GJ. The management of chronic spinal pain by blocks: A review. *Pain* 1994;58:1-20.
2. Krempen JF, Smith BS. Nerve-root injection. A method for evaluating etiology in sciatica. *J Bone Joint Surg* 1974;56A:1435-1444.
3. Tajima T, Furukawa K, Kuramochi E. Selective lumbosacral radiculography block. *Spine* 1980;5:68-77.
4. Herron LD. Selective nerve root block in patient selection for lumbar surgery: Surgical results. *J Spine Dis* 1989;2:75-79.
5. Dooley JF, McBroom RJ, Taguchi T, Macnab I. Nerve root infiltration in the diagnosis of radicular pain. *Spine* 1988;13:79-83.
6. Head H, Campbell AW. The pathology of herpes zoster and its bearing on sensory location. *Brain* 1900; 23:353-523.
7. Bolk L. *De segmentale innervatie van romp en ledematen bij den mensch*. Haarlem, The Netherlands: De Erven F. Bohn; 1910:1-152.
8. Sherrington CS. Experiments in examination of the peripheral distribution of the fibers of the posterior roots of some spinal nerves. *Philos Trans R Soc Lond B* 1893;184:641-764.
9. Keegan JJ, Garrett FD. The segmental distribution of



- the cutaneous nerves in the limbs of man. *Anat Rec* 1948;102:409-437.
10. Hansel K, Schliack H. *Segmentale Innervation. Ihre Bedeutung für Klinik und Praxis*, 2nd ed. Stuttgart, Germany: Thieme Verlag; 1962.
  11. Brodal A. *Neurological Anatomy in Relation to Clinical Medicine*, 3rd ed. New York, NY: Oxford University Press; 1981:69-74.
  12. Nitta H, Tajima T, Sugiyama H, Moriyama A. Study on dermatomes by means of selective lumbar nerve block. *Spine* 1993;13:1782-1786.
  13. North RB, Kidd DH, Zahurak M, Piantadosi S. Specificity of diagnostic nerve blocks: A prospective, randomised study of sciatica due to lumbosacral spine disease. *Pain* 1996;5:77-85.
  14. Foerster O. The dermatomes in man. *Brain* 1933;56: 1-39.
  15. Sherrington CS. Experiments in examination of the peripheral distribution of the fibers of the posterior roots of some spinal nerves. *Philos Trans R Soc Lond B* 1898;190:45-186.
  16. Fletcher TF, Kitchell RL. The lumbar, sacral and coccygeal tactile dermatomes of the dog. *J Comp Neurol* 1966;128:171-180.
  17. Pubols BH Jr, Welker WI, Johnson JI Jr. Somatic sensory representation of forelimb in dorsal fibers of raccoon, coatimundi and cat. *J Neurophysiol* 1965;28: 312-341.
  18. Hekmatpanah J. Organization of tactile dermatomes, C1 through L4, in cat. *J Neurophysiol* 1961;24:129-140.
  19. Takahashi Y, Nakajima Y. Dermatomes in the rat limbs as determined by antidromic stimulation of sensory C-fibers in spinal nerves. *Pain* 1996;67:197-202.
  20. Dux M, Jancsó G. A new technique for the direct demonstration of overlapping cutaneous innervation territories of peptidergic C-fibre afferents of rat hind-limb nerves. *J Neurosci Methods* 1994;55:47-52.
  21. Kirk EJ. The dermatomes of the sheep. *J Comp Neurol* 1968;134:353-369.
  22. Kukulinsky DH, Brown PB. Cat L4-S1 dermatomes determined using signal averaging. *Neurosci Lett* 1997; 13:79-82.
  23. Oswaldo-Cruz E, Pagani R, Rocha-Miranda CE. Lumbar and sacral dermatomes in the opossum. *An Acad Bras Cienc* 1965;37:337-344.
  24. Bell-Krotoski J. Pocket filaments and specifications for the SW monofilaments. *J Hand Surg Ther* 1990; January-March: 26-31.
  25. Bell-Krotoski J, Tomancik E. The repeatability of testing with Semmes-Weinstein monofilaments. *J Hand Surg Ther* 1987;12:155-161.