

Neurology®

The most widely read and highly cited peer-reviewed neurology journal  
The Official Journal of the American Academy of Neurology



Neurology Publish Ahead of Print

DOI: 10.1212/WNL.000000000201705

Clinical Reasoning: A 26-Year-Old Female With Recurrent Pain, Weakness, and Atrophy in Bilateral  
Upper Limbs During Pregnancy and Puerperium

**Author(s):**

Tian-fang Zeng, M.D.<sup>1</sup>; Xin Ding, M.D.<sup>1</sup>; Dan Yang, M.D.<sup>1</sup>; Chang-Chuan Wu, M.D.<sup>1</sup>; Dan-Dan  
Xie, M.D.<sup>1</sup>; Wen-Min Zhang, M.D.<sup>2</sup>

**Corresponding Author:**

Xin Ding, dingxin105@163.com

Neurology® Published Ahead of Print articles have been peer reviewed and accepted for publication. This manuscript will be published in its final form after copyediting, page composition, and review of proofs. Errors that could affect the content may be corrected during these processes.

---

**Affiliation Information for All Authors:** 1. Department of Neurology, Cheng Du Second People's Hospital, Chengdu, China; 2. Chengdu Medical College, Chengdu, China

**Equal Author Contribution:**

Tian-fang Zeng and Xin Ding are co-first authors

**Contributions:**

Tian-fang Zeng: Drafting/revision of the manuscript for content, including medical writing for content

Xin Ding: Drafting/revision of the manuscript for content, including medical writing for content; Study concept or design

Dan Yang: Study concept or design

Chang-Chuan Wu: Major role in the acquisition of data

Dan-Dan Xie: Analysis or interpretation of data

Wen-Min Zhang: Analysis or interpretation of data

---

**Figure Count:**

1

**Table Count:**

1

**Search Terms:**

[ 16 ] Clinical neurology examination, [ 285 ] EMG, [ 94 ] Genetic linkage, [ 181 ] Peripheral neuropathy, [ 224 ] Neuropathic pain

**Acknowledgment:**

**Study Funding:**

The authors report no targeted funding

**Disclosures:**

The authors report no relevant disclosures.

**Preprint DOI:**

**Received Date:**

---

2022-04-24

**Accepted Date:**

2022-11-03

**Handling Editor Statement:**

Submitted and externally peer reviewed. The handling editor was Whitley Aamodt, MD, MPH.

**Abstract**

We present a case of a 26-year-old female with recurrent episodes of severe pain, weakness, and atrophy in her bilateral upper extremities during pregnancy and puerperium. She reported two similar episodes at ages five and ten, after which she fully recovered. On examination, we observed significant atrophy in her bilateral upper extremity muscles with decreased strength. Needle electromyography (EMG) revealed neurogenic damage in her bilateral upper limbs. The patient's clinical manifestations and auxiliary examination suggested a brachial plexopathy. Metabolic and immune factors that may occur during pregnancy and puerperium were evaluated. We also screened for paraneoplastic, neoplastic, and genetic factors. Finally, a hereditary form of disease was considered. This case emphasizes the importance of early diagnosis and avoidance of triggers.

**Section 1**

A 26-year-old female developed tingling in her right upper limb during the

---

second month of pregnancy that progressed to her left upper limb within several days. The pain, which first appeared at night, worsened during cold weather and improved when it was hot. Two weeks later, she developed proximal weakness in her right more than left arm. She also noticed progressive difficulty lifting her arms, using chopsticks, and buttoning clothes. There was no history of antecedent trauma, infection, or vaccination. The patient did not take any medication and was referred for rehabilitation therapy. The pain gradually resolved 3 months later, and the weakness in both arms slowly improved. She was eventually able to manage her daily activities without assistance, but had mild residual weakness.

One week after giving birth, the patient experienced another attack. She developed severe pain in the left shoulder and arm, numbness in the left hand, and could not raise her left arm. After a few days, she developed weakness and pain in both upper limbs. No neck pain, bowel/bladder dysfunction, or muscle fasciculations were reported. She denied weakness or sensory change in her lower limbs. She reported having two similar episodes at ages five and ten, after which she fully recovered. With regard to family history, her mother also reported a similar, single episode that started with muscle weakness in the right upper extremity one month after parturition, from which she recovered eight months later.

On examination, mental status was normal and cranial nerves were intact. Strength in the upper extremities was decreased (**Figure, A**). The patient had normal strength in the lower extremities. Tone was decreased in the arms and normal in the

---

legs. Significant atrophy of bilateral infraspinatus, teres minor, and deltoid muscles were observed, in addition to decreased sensation to pinprick along the radial aspect of the forearms. No fasciculations were noted. Deep tendon reflexes (DTRs) were 1+ in the upper limbs and 2+ in the lower limbs. No pathological reflexes were found. The patient had a similar facial appearance as her mother, as both had hypotelorism (measured pupil-to-pupil with a ruler) (**Figure, B**).

**Question for consideration:**

1. Where would you localize the lesion?

**Section 2**

The severe pain, numbness, and weakness with focal muscle atrophy in the bilateral upper limbs and depressed reflexes suggest involvement of the peripheral nervous system. The central nervous system is less likely involved in the absence of upper motor neuron signs. Therefore, we considered a multilevel radicular process involving multiple nerve roots (C5-T1), brachial plexopathy, or neuropathy (radial, median, axillary, suprascapular, and musculocutaneous nerves). The patient also experienced significant pain during each attack. The differential diagnosis based on localization might involve the following:

1. Radiculopathy, which can be caused by trauma or various inflammatory or neoplastic disorders, but does not typically involve the bilateral upper extremities simultaneously.

- 
2. Plexopathy, such as Parsonage-Turner syndrome or diabetic radiculoplexus neuropathies, which can be associated with severe pain at the onset of weakness.
  3. Multiple mononeuropathies, which can be caused by vasculitis, inflammation, or diabetic neuropathy, and result in neuropathic pain.

**Question for consideration:**

1. What is the most appropriate next step in this patient's work-up?

**Section 3**

Needle electromyography (EMG) and nerve conduction studies (NCS) were performed after the fourth attack. EMG revealed neurogenic damage in the bilateral upper limbs. Sensory nerve conduction studies also showed a low-amplitude right radial nerve sensory nerve action potential (SNAP) and slow sensory conduction velocity of the right median nerve and bilateral radial nerves. The motor nerve conduction testing showed decreased compound muscle action potential (CMAP) amplitudes elicited bilaterally from the axillary, radial, and musculocutaneous nerves and right median nerve (**Table**). The above findings revealed dysfunction in the middle and upper trunci of the bilateral brachial plexus.

The patient's clinical manifestations and auxiliary examination suggested a brachial plexus neuropathy; however, she had no history of recent infection, trauma, vaccination, cancer, toxic exposure, diabetes, or radiation therapy. Laboratory tests,

---

including erythrocyte sedimentation rate, antinuclear antibodies, and antineutrophil cytoplasmic antibodies were within normal limits. Cerebrospinal fluid tests were normal. Immunological testing for anti-ganglioside and anti-Hu paraneoplastic antibodies was negative. Contrast-enhanced MRI of the brachial plexus and cervical spine was normal. Considering the high rate of recurrence, family history, and presence of dysmorphic features, a hereditary disease was suspected.

Questions for consideration:

1. What hereditary disease could account for patient's symptoms?
2. What testing is required for definitive diagnosis?

#### **Section 4**

When evaluating patients for a genetic disease involving the brachial plexus, hereditary neuralgic amyotrophy (HNA) should be considered. Gene analyses were performed for HNA. We identified a heterozygous single nucleotide change c.316C > T in exon 3 of the SEPT9 gene (GRCh37/hg19 chr17:75398380), resulting in the amino acid change p.R106W (**Figure, C**). This mutation was also found in the patient's mother and son (**Figure, D**). The son was two months old at time of genetic testing.

#### **Discussion**

Neuralgic amyotrophy (NA) is clinically characterized by the sudden onset of extreme neuropathic pain in the upper limbs, followed by weakness and atrophy of the



---

affected muscles and occasional sensory deficits, with slow recovery over months to years<sup>1</sup>. Neuralgic amyotrophy has an idiopathic form (INA, also called Parsonage-Turner syndrome) and an autosomal dominant hereditary form (HNA). Compared to INA, HNA is much rarer<sup>2, 3</sup>. Single HNA episodes strongly resemble INA. The striking similarities include pain, predilection for the arm plexus, and provocation by the same triggers<sup>4</sup>. Distinguishing features include family history, earlier age of onset, higher rate of recurrence, and the presence of dysmorphic features in HNA, which are noteworthy in our case.

The European CMT Consortium developed the first diagnostic guidelines for HNA<sup>5</sup>. Subsequently, Alfen et al. supplemented the characteristics of HNA<sup>6</sup>. They proposed core features of HNA as follows: 1) acute, uni- or bilateral brachial plexopathy; 2) severe pain precedes onset of weakness by days to few weeks; 3) predominantly motor deficits; 4) number of episodes variable (1-20); 5) precipitating factors: infections, immunizations, surgery, pregnancy, parturition, unusually strenuous exercise of affected limb, exposure to cold. In our study, the patient suffered from attacks during pregnancy and after delivery. The onset of HNA usually occurs in the second or third decade of life, though earlier and later onset is possible. HNA can run two distinct courses: a relapsing/remitting course with symptom-free intervals or incomplete recovery, characterized by persistent neurologic deficits after repeated attacks in the same limb<sup>6, 7</sup>.

Several authors have also noted minor dysmorphic features associated with HNA. These include a long, narrow face, small mouth, hypotelorism (close-set eyes),

---

shortened palpebral fissures, epicanthal folds, cleft palate, minor syndactyly, circular skin creases, long nasal bridge, and short stature<sup>8,9</sup>. Both our patient and her mother have mild dysmorphic features, such as hypotelorism, which can help differentiate HNA from idiopathic neuralgic amyotrophy<sup>5</sup>.

With regard to genetics, hereditary neuralgic amyotrophy (Online Mendelian Inheritance in Man catalog, OMIM 162100) is an autosomal dominant disorder associated with pathogenic mutations in the SEPT9 gene on chromosome 17q25.3<sup>10,11</sup>. To date, three point mutations (c.-131G > C, c.262C > T, and c.278C > T) and a genetic founder haplotype have been identified in HNA pedigrees supporting a critical role for the SEPT9 gene<sup>8,12,13</sup>. In general, HNA is genetically heterogeneous and has been linked to a mutation or duplication in the SEPT9 gene in only 55% of affected families<sup>14</sup>. One or more unknown genes may also be associated with HNA<sup>3</sup>.

So far, sequence analysis of SEPT9 in larger cohorts of HNA families has not identified any additional mutations beyond those previously reported<sup>11,14</sup>. In this study, our patient had an unusual heterozygous mutation with typical HNA symptoms, NM\_001113491.1p.R106W (c.316C>T), located on exon 3 of the SEPT9 gene. Genetic analyses suggested a heterozygous mutation in the SEPT9 gene in three generations, the patient, her mother, and her son.

Currently, there is no standardized approach for treatment. Some case series suggest that early corticosteroid therapy or i.v. immunoglobulin may benefit patients in the acute phase of NA<sup>15</sup>. This case emphasizes the importance of early diagnosis and avoidance of triggers. HNA should be highly suspected when a patient presents

with severe pain followed by weakness and atrophy of the upper extremities. Although we found a gene locus that might be responsible for HNA, the significance of this finding should be verified in subsequent studies.

**Table. Nerve conduction studies and EMG**

<b>CMAP</b>	<b>Stimulation site</b>	<b>Recording site</b>	<b>Latency, ms</b>	<b>Amplitude (motor mV, Sensory <math>\mu</math>V)</b>	<b>Conduction velocity, m/s</b>
<b>R median</b>	Wrist	APB	3.80(<4)	0.7 (>5)	
	Elbow	APB	7.81	0.4(>5)	54(>50)
<b>L median</b>	Wrist	APB	2.50(<4)	6.4(>5)	
	Elbow	APB	5.52	5.5(>5)	73(>50)
<b>R ulnar</b>	Wrist	ADM	1.88(<3.8)	7.1(>5)	
	Below elbow	ADM	5.00	8.2(>5)	74(>50)
<b>L ulnar</b>	Wrist	ADM	2.24(<3.8)	11.2(>5)	

	Below elbow	ADM	5.05	9.4(>5)	82(>50)
<b>R radial</b>	Forearm	EIP	4.06	0.3(>8)	-
<b>L radial</b>	Forearm	EIP	4.38	0.3(>8)	-
<b>R musculocutaneous nerve</b>	Erb's	Biceps	5.99	1.4(>6)	-
<b>L musculocutaneous nerve</b>	Erb's	Biceps	4.84	1.2(>6)	-
<b>R axillary nerve</b>	Erb's	Deltoid	3.23	1.2(>6)	-
<b>L axillary nerve</b>	Erb's	Deltoid	4.48	3.0(>6)	-
<b>R tibial</b>	Ankle	AH	2.71(<5)	18.0(>4)	
<b>L peroneal</b>	Ankle	EDB	3.80(<5)	6.3(>3)	
<b>SNAP</b>					
<b>R median</b>	Wrist	Digit II	5.94	43.7(>10)	26(>50)
<b>L median</b>	Wrist	Digit II	2.45	65.0(>10)	65(>50)
<b>R ulnar</b>	Wrist	Digit V	2.34	56.3(>10)	58(>50)
<b>L ulnar</b>	Wrist	Digit V	2.19	32.0(>10)	60(>50)
<b>R radial</b>	Forearm	Anatomical snuff box	2.97	2.90(>10)	45(>50)

<b>L radial</b>	Forearm	Anatomical snuff box	2.92	20.5(>10)	45(>50)
<b>EMG</b>	<b>Spontaneous activity</b>		<b>Motor unit morphology</b>		<b>Recruitment</b>
	Fibs/PSWs	Fasciculation	Amplitude	Duration	
<b>L deltoid</b>	3+	-	No units	No units	No units
<b>L biceps</b>	1+	-	Normal	Normal	Decreased
<b>L EDC</b>	2+	-	No units	No units	No units
<b>L APB</b>	1+	-	No units	No units	No units
<b>R deltoid</b>	2+	-	Normal	Normal	No units
<b>R biceps</b>	2+	-	Increased	Increased	Decreased
<b>R EDC</b>	3+	-	Increased	Increased	No units
<b>R APB</b>	3+	-	No units	No units	No units
<b>L anterior tibialis</b>	-	-	Normal	Normal	Normal
<b>R vastus medialis</b>	-	-	Normal	Normal	Normal

Abbreviations: CMAP = compound muscle action potential; SNAP = sensory nerve action potential; APB = abductor pollicis brevis; ADM = abductor digiti minimi; EIP = extensor indicis proprius; EDB = extensor digitorum brevis; AH = abductor hallucis; EDC = extensor digitorum communis; EMG = Needle electromyography; Fibs/PSWs

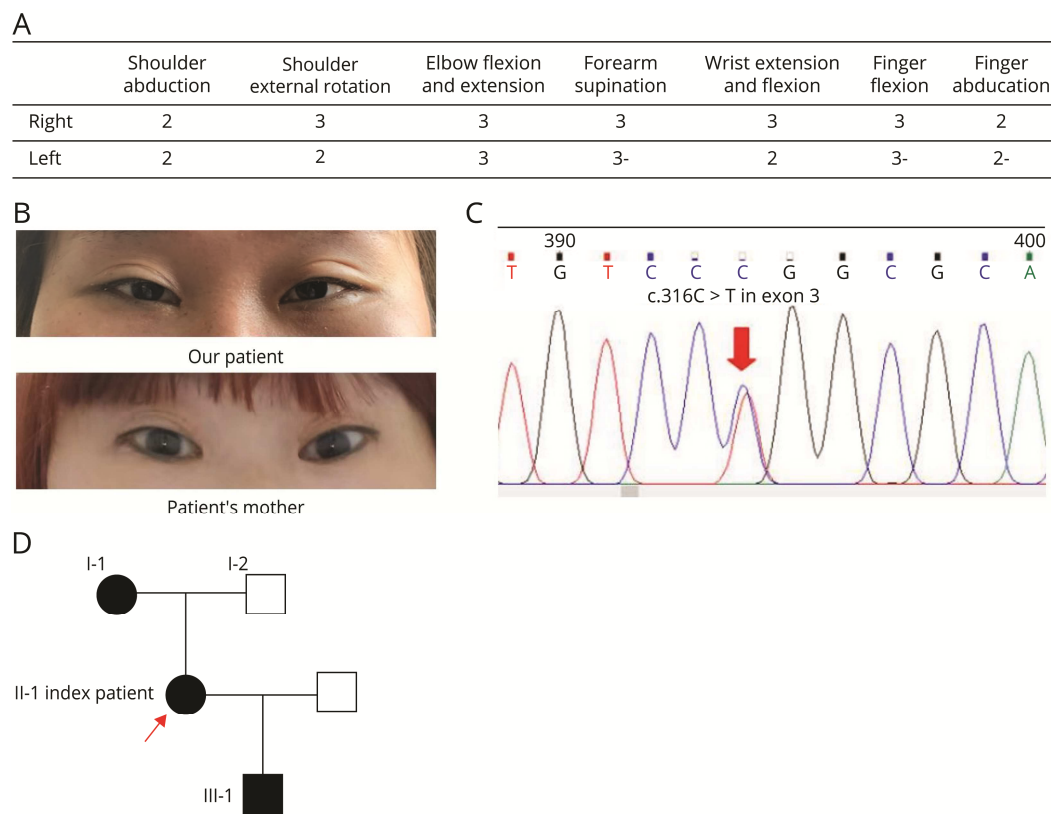
---

= fibrillation potentials or positive sharp waves

Annotation: The values in parentheses are reference normal values.

ACCEPTED

## Figure. Clinical and gene findings



(A) Strength in the upper extremities (Medical Research Council); (B) Dysmorphic features; (C) A heterozygous single nucleotide change c.316C > T in exon 3 of the SEPT9 gene, resulting in the amino acid change p.R106W; (D) Pedigree: Females are shown as circles, males as squares. Filled symbols represent affected individuals with an exon 3 missense mutation of the SEPT9 gene. Open symbols indicate non-affected individuals and a slanting arrow the index patient. III. I is without attack so far.

---

## REFERENCES

1. van Alfen N, van Eijk JJ, Ennik T, et al. Incidence of neuralgic amyotrophy (Parsonage Turner syndrome) in a primary care setting--a prospective cohort study. *PLoS One* 2015;10:e0128361.
2. Parsonage MJ, Turner JW. Neuralgic amyotrophy; the shoulder-girdle syndrome. *Lancet* 1948;1:973-978.
3. Neubauer K, Boeckelmann D, Koehler U, et al. Hereditary neuralgic amyotrophy in childhood caused by duplication within the SEPT9 gene: A family study. *Cytoskeleton (Hoboken)* 2019;76:131-136.
4. Meuleman J, Timmerman V, Van Broeckhoven C, De Jonghe P. Hereditary neuralgic amyotrophy. *Neurogenetics* 2001;3:115-118.
5. Kühlenbäumer G, Stögbauer F, Timmerman V, De Jonghe P. Diagnostic guidelines for hereditary neuralgic amyotrophy or hereditary familial neuritis with brachial plexus predilection. On behalf of the European CMT Consortium. *Neuromuscul Disord* 2000;10:515-517.
6. van Alfen N, Hannibal MC, Chance PF, van Engelen BGM. Hereditary Neuralgic Amyotrophy – RETIRED CHAPTER, FOR HISTORICAL REFERENCE ONLY. In: Adam MP, Everman DB, Mirzaa GM, et al., eds. *GeneReviews*(®). Seattle (WA): University of Washington, Seattle  
  
Copyright © 1993-2022, University of Washington, Seattle. GeneReviews is a registered trademark of the University of Washington, Seattle. All rights reserved., 1993.



- 
7. van Alfen N, van Engelen BG, Reinders JW, Kremer H, Gabreëls FJ. The natural history of hereditary neuralgic amyotrophy in the Dutch population: two distinct types? *Brain* 2000;123 ( Pt 4):718-723.
  8. Laccone F, Hannibal MC, Neesen J, Grisold W, Chance PF, Rehder H. Dysmorphic syndrome of hereditary neuralgic amyotrophy associated with a SEPT9 gene mutation--a family study. *Clin Genet* 2008;74:279-283.
  9. Jeannot PY, Watts GD, Bird TD, Chance PF. Craniofacial and cutaneous findings expand the phenotype of hereditary neuralgic amyotrophy. *Neurology* 2001;57:1963-1968.
  10. Wehnert M, Timmerman V, Spoelders P, Meuleman J, Nelis E, Van Broeckhoven C. Further evidence supporting linkage of hereditary neuralgic amyotrophy to chromosome 17q. *Neurology* 1997;48:1719-1721.
  11. Hannibal MC, Ruzzo EK, Miller LR, et al. SEPT9 gene sequencing analysis reveals recurrent mutations in hereditary neuralgic amyotrophy. *Neurology* 2009;72:1755-1759.
  12. Kuhlenbäumer G, Hannibal MC, Nelis E, et al. Mutations in SEPT9 cause hereditary neuralgic amyotrophy. *Nat Genet* 2005;37:1044-1046.
  13. Ueda M, Kawamura N, Tateishi T, et al. Phenotypic spectrum of hereditary neuralgic amyotrophy caused by the SEPT9 R88W mutation. *J Neurol Neurosurg Psychiatry* 2010;81:94-96.
  14. Collie AM, Landsverk ML, Ruzzo E, et al. Non-recurrent SEPT9 duplications cause hereditary neuralgic amyotrophy. *J Med Genet* 2010;47:601-607.

---

15. J IJ, Janssen RMJ, van Alfen N. Neuralgic amyotrophy. *Curr Opin Neurol* 2021;34:605-612.

ACCEPTED

# Neurology®

## Clinical Reasoning: A 26-Year-Old Female With Recurrent Pain, Weakness, and Atrophy in Bilateral Upper Limbs During Pregnancy and Puerperium

Tian-fang Zeng, Xin Ding, Dan Yang, et al.

*Neurology* published online December 15, 2022

DOI 10.1212/WNL.0000000000201705

**This information is current as of December 15, 2022**

<b>Updated Information &amp; Services</b>	including high resolution figures, can be found at: <a href="http://n.neurology.org/content/early/2022/12/15/WNL.0000000000201705.full">http://n.neurology.org/content/early/2022/12/15/WNL.0000000000201705.full</a>
<b>Subspecialty Collections</b>	This article, along with others on similar topics, appears in the following collection(s): <b>Clinical neurology examination</b> <a href="http://n.neurology.org/cgi/collection/clinical_neurology_examination">http://n.neurology.org/cgi/collection/clinical_neurology_examination</a> <b>Cluster headache</b> <a href="http://n.neurology.org/cgi/collection/cluster_headache">http://n.neurology.org/cgi/collection/cluster_headache</a> <b>EMG</b> <a href="http://n.neurology.org/cgi/collection/emg">http://n.neurology.org/cgi/collection/emg</a> <b>Genetic linkage</b> <a href="http://n.neurology.org/cgi/collection/genetic_linkage">http://n.neurology.org/cgi/collection/genetic_linkage</a> <b>Neuropathic pain</b> <a href="http://n.neurology.org/cgi/collection/neuropathic_pain">http://n.neurology.org/cgi/collection/neuropathic_pain</a> <b>Peripheral neuropathy</b> <a href="http://n.neurology.org/cgi/collection/peripheral_neuropathy">http://n.neurology.org/cgi/collection/peripheral_neuropathy</a>
<b>Permissions &amp; Licensing</b>	Information about reproducing this article in parts (figures, tables) or in its entirety can be found online at: <a href="http://www.neurology.org/about/about_the_journal#permissions">http://www.neurology.org/about/about_the_journal#permissions</a>
<b>Reprints</b>	Information about ordering reprints can be found online: <a href="http://n.neurology.org/subscribers/advertise">http://n.neurology.org/subscribers/advertise</a>

*Neurology*® is the official journal of the American Academy of Neurology. Published continuously since 1951, it is now a weekly with 48 issues per year. Copyright © 2022 American Academy of Neurology. All rights reserved. Print ISSN: 0028-3878. Online ISSN: 1526-632X.

