

# The Surgical Anatomy of Lumbar Medial Branch Neurotomy (Facet Denervation)

Peter Lau, FRACR,\* Susan Mercer, PhD,<sup>†</sup> Jayantilal Govind, FAFOM,\* and Nikolai Bogduk, DSc\*

\*Department of Clinical Research, University of Newcastle, Royal Newcastle Hospital, Newcastle, Australia;

<sup>†</sup>Department of Anatomy, University of Otago, Dunedin, New Zealand

## ABSTRACT

*Objective.* To demonstrate the validity of placing electrodes parallel to the target nerve in lumbar radiofrequency neurotomy.

*Design.* Previous data on the anatomy of the lumbar dorsal rami were reviewed and a demonstration cadaver was prepared. Under direct vision, electrodes were placed on, and parallel to, the L4 medial branch and the L5 dorsal ramus. Photographs were taken to record the placement, and radiographs were taken to illustrate the orientation and location of the electrode in relation to bony landmarks.

*Results.* In order to lie in contact with, and parallel to, the target nerve, electrodes need to be inserted obliquely from below, so that their active tip crosses the neck of the superior articular process. At typical lumbar levels, the tip should lie opposite the middle two quarters of the superior articular process. At the L5 level, it should lie opposite the middle and posterior thirds of the S1 superior articular process.

*Conclusion.* If electrodes are placed parallel to the target nerve, the lesions made can be expected to encompass the target nerves. If electrodes are placed perpendicular to the nerve, the nerve may escape coagulation, or be only partially coagulated. Placing the electrode parallel to the nerve has a demonstrated anatomical basis, and has been vindicated clinically. Other techniques lack such a basis, and have not been vindicated clinically. Suboptimal techniques may underlie suboptimal outcomes from lumbar medial branch neurotomy.

*Key Words.* Back Pain; Neurotomy; Denervation; Zygapophysial Joint; Medial Branch; Nerves

## Introduction

When first described, lumbar facet denervation was based on an incorrect description of anatomy. Shealy [1] described the articular branches to the lumbar zygapophysial joints as rising dorsally across the lateral aspect of the superior articular processes. Accordingly, he recommended placing electrodes lateral to the articular process, perpendicular to the coronal plane [2–5].

It was subsequently shown that the medial branch of each lumbar dorsal ramus runs caudally across the neck of the superior articular process and that articular branches approach each joint from below and from above [6–9]. No nerve rises dorsally through the region where Shealy recommended placing electrodes [1].

For the purposes of denervating a zygapophysial joint, the articular branches are too small to be accurately targeted, but their parent medial branch can be targeted. An electrode placed at the junction of the superior articular process with the root of the transverse process would rest on the medial branch. On this basis, lumbar facet denervation was modified to become lumbar medial branch neurotomy [6,7]. Not all

*Reprint requests to:* Nikolai Bogduk, D.Sc., Department of Clinical Research, Royal Newcastle Hospital, Newcastle, New South Wales 2300, Australia. Tel: 61-2-49236172; Fax: 61-2-49236103; E-mail: mgillam@mail.newcastle.edu.au.

operators, however, heeded this explanation of the correct anatomy. They continued to use the discredited Shealy approach [10,11], even in controlled trials [12].

Another modification followed when it was demonstrated that radiofrequency electrodes do not effectively coagulate tissues distal to their tip; they coagulate in a radial direction around the exposed tip, perpendicular to the long axis of the electrode [13]. Consequently, an electrode whose tip is placed perpendicular to the target nerve may fail to coagulate the nerve adequately. Depending on how far the electrode coagulates distal to its tip, it may coagulate the nerve only partially or it may fail to coagulate the nerve at all. From a partial coagulation, the nerve may rapidly recover, resulting in relief from pain of only a limited duration. For the target nerve to be coagulated reliably and thoroughly, the electrode must be placed parallel to the nerve [13].

This technical warning has not been heeded. Only one study has described the outcomes of lumbar medial branch neurotomy in which the electrode was properly placed parallel to the target nerve [14]. With this technique, good results can be obtained. Some 60% of patients maintain at least 80% relief of their pain at 12 months, and some 80% of patients maintain at least 60% relief. That study, however, was based on a small sample of highly selected patients. Its outcomes have still to be corroborated in a larger sample. Nevertheless, it remains the only published study of parallel placement of electrodes.

Others have persisted in using techniques that have not been validated anatomically. Most still advocate placing the tip of the electrode onto the base of the transverse process in order to reach the medial branch. However, all variants still have the electrode essentially perpendicular to the course of the nerve and rely on lesions being made distal to the tip. Of those techniques that have been tested clinically, one has been found to be totally ineffective [15]; others have been partially effective at 6-week [16] and 8-week [17] follow-ups. Other variants have been described but not tested clinically [18–20].

Ironically, the literature actually lacks any description that validates what should be the correct placement of electrodes for lumbar medial branch neurotomy. Authorities writing on this topic rely only on verbal descriptions of anatomy to justify their technique. Citing articles that state that the medial branch crosses the root of the transverse process, they advocate placing elec-

trodes onto this bony landmark. No study has shown how electrodes placed in various positions actually relate to the target nerve. The present study was, therefore, undertaken to anatomically validate why electrodes should be placed parallel to the target nerve.

## Methods

The records of data previously reported in anatomical studies [8] were reviewed to establish the course of the medial branches of the lumbar dorsal rami. These data covered 30 nerves in six cadavers. For purposes of illustration, another cadaver was freshly dissected on one side, under a dissecting microscope, to provide a specimen with the medial branches in situ, but the surrounding muscles removed.

Under direct vision, an electrode was placed both parallel to and in contact with the target nerve at the L4 and at the L5 level. Photographs were taken to illustrate both the nerve alone and the electrode in contact with the nerve. With the electrode held in place, anteroposterior (AP), lateral, and declined radiographs were taken of the electrode position using a C-arm fluoroscope.

For the declined views, the X-ray beam was tilted laterally by 20° from an AP view and then declined steeply along the length of the body until a view was obtained along the course of the electrode, that is, end-on, from below.


In order to demonstrate the sizes of lesions made by radiofrequency electrodes in relation to the target nerves, ellipses representing the outer boundaries of lesions were drawn to scale on photographs and radiographs of electrodes placed against the nerve. Such ellipses have a longitudinal and a transverse axis, the lengths of which differ for different electrodes. Laboratory studies have measured the mean sizes of the lesions made by SMK and RRE electrodes (Radionics; Burlington, MA) with 5-mm active tips [21]. Respectively, the active tips of these electrodes are 0.7 mm and 1.6 mm wide. In order to circumvent errors caused by magnification and projection, the sizes of lesions made by these electrodes can be expressed in terms of electrode-widths. The lesions made by an SMK electrode have a mean transverse diameter of 5.6 ( $\pm 0.8$  SD) electrode-widths and a mean longitudinal diameter of 8.5 ( $\pm 0.4$  SD) electrode-widths. Those made by an RRE electrode have a mean transverse diameter of 4.2 ( $\pm 0.6$  SD) electrode-widths and a mean longitudinal diameter of 3.5 ( $\pm 0.2$  SD) electrode-widths. In the present

study, ellipses were drawn of a size corresponding to the mean size of the lesions made by the two types of electrode.

## Results

The medial branches of the dorsal rami at segmental levels L1 to L4 assume a constant and similar course. Each nerve emerges from its intervertebral foramen and enters the posterior compartment of the back by coursing around the neck of the superior articular process below the foramen (Figure 1). Still hugging the neck of the superior articular process, the medial branch passes caudally and slightly dorsally to disappear under the mamillo-accessory ligament [22]. Beneath the ligament, the nerve hooks medially around the caudal aspect of the root of the superior articular process to enter the multifidus muscle. Intermediate and lateral branches arise from the dorsal ramus at the same point as the medial branch. These nerves run caudally and laterally, across the transverse process, into the longissimus and iliocostalis muscles, respectively (Figure 1).

Two anatomical features govern the constancy of the course of each medial branch. Its point of entry into the posterior compartment is fixed. It enters that compartment through a foramen in the posterior leaf of the intertransverse ligament [23]



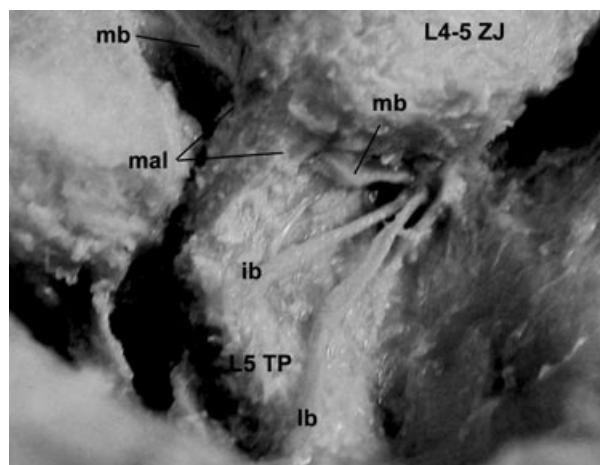
**Figure 1** A dissection of the right L5 dorsal ramus and the branches of the L4 dorsal ramus, viewed dorsally from the right, peering over the dorsal segment of the right iliac crest. Abbreviations: PF = posterior sacral foramen; ZJ = zygapophysial joint; TP = transverse process; dr = dorsal ramus; mb = medial branch; ib = intermediate branch; lb = lateral branch; cb = communicating branch; mal = mamillo-accessory ligament.

immediately rostral to the junction of the superior articular process and transverse process. Caudally, the nerve is again fixed by the mamillo-accessory ligament. Fixation of the nerve by the mamillo-accessory ligament allows for virtually no variation in the location or orientation of the nerve as it crosses the neck of the superior articular process. Such variations as do occur are governed by the height of the accessory process and the depth of the mamillo-accessory notch. This can affect the slope of the medial branch as it crosses the neck of the superior articular process by a few degrees, but the nerve always crosses the neck. For the purposes of medial branch neurotomy, the nerve can be considered as always held against the superior articular process by the mamillo-accessory ligament.

At the L5 level, the anatomy is different. The L5 dorsal ramus is much longer than at typical lumbar levels. From the L5-S1 intervertebral foramen, it runs along the groove formed between the ala of the sacrum and the root of the S1 superior articular process (Figure 1). Opposite the caudal end of the superior articular process, its medial branch hooks medially around the caudal aspect of that process, running deep to some fibrous tissue that constitutes the analog of the mamillo-accessory ligament at this level (Figure 1). A communicating branch to the S1 dorsal ramus continues the longitudinal course of the dorsal ramus.

For the safe and accurate execution of radiofrequency neurotomy, the medial branch at typical lumbar levels is accessible for only a limited length: opposite the middle two fourths of the neck of the superior articular process (Figure 2). Distal to this area, the nerve lies under the mamillo-accessory ligament and it is protected from coagulation by the ligament. Proximal to this area, the medial branch lies close to the origin and proximal course of the intermediate and lateral branches of the dorsal ramus. If these latter branches are to be avoided, the electrode should not be inserted opposite the ventral fourth of the neck of the superior articular process.

An electrode with a 5-mm active tip can be placed in both of two positions along a typical medial branch (Figure 3). At the deeper position, the point of the electrode lies opposite the junction of the first and second ventral quarters of the superior articular process. Here, it approaches the origin of the medial branch and that of its companion intermediate and lateral branches. At the second position, the electrode is withdrawn by 3–



**Figure 2** A close-up view of the branches of a right L4 dorsal ramus, viewed from the right. For the execution of medial branch neurotomy, the medial branch is accessible along only a short length between its origin from the dorsal ramus and the point at which it disappears under the mamillo-accessory ligament. Abbreviations: ZJ = zygapophysial joint; TP = transverse process; ib = intermediate branch; lb = lateral branch; mb = medial branch; mal = mamillo-accessory ligament.

5 mm so that its point lies opposite the middle of the neck of the superior articular process. Distal to this latter position, the electrode loses contact with the medial branch because the nerve disappears under the mamillo-accessory ligament. An electrode with a 10-mm active tip can be placed in a single location that covers both placements described above for electrodes with a 5-mm tip.

Electrodes lying parallel to a medial branch, and in contact with it, assume characteristic appearances on radiographs. In a declined view, the electrode crosses the neck of the superior articular process (Figure 4). It lies against the bottom of the lateral surface of the superior artic-


ular process rather than on the root of the transverse process. This appearance applies irrespective of whether the electrode lies in the deep or in the withdrawn position.

In lateral views, the electrode is seen to cross the neck of the superior articular process (Figure 5). In the deeper position, the distal tip of the electrode reaches the anterior quarter of the neck of the superior articular process. In the withdrawn position, the tip lies opposite the middle of the neck of the superior articular process.

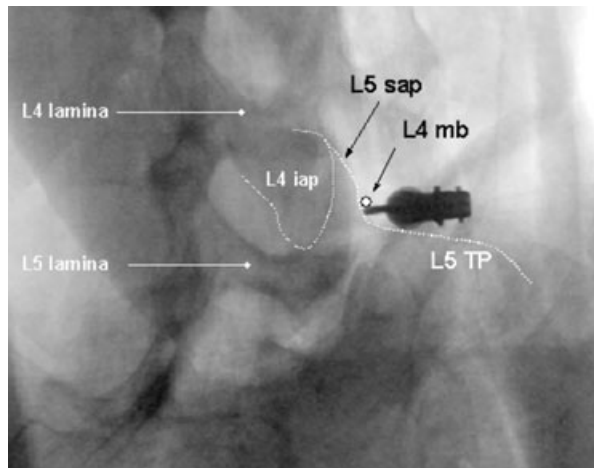
Anteroposterior views demonstrate several features (Figure 6). First, the electrode must lie obliquely, at about 20° from the sagittal plane. This is to avoid the accessory process and mamillo-accessory ligament, which may obstruct the course of the electrode if it is inserted along a parasagittal plane lateral to the superior articular process. As a result, the electrode appears to hug the anterolateral aspect of the base of the superior articular process in the AP view.

Secondly, the electrode lies hard up against the superior articular process. This is reflected by the electrode lying medial to the silhouette of the lateral margin of the dorsal end of the superior articular process, which projects slightly more laterally than does the lateral margin of the neck of the process (against which the electrode lies).

Thirdly, the tip of the electrode appears to project beyond the rostral edge of the transverse process and into the intervertebral foramen. However, this appears to be the case only if the reference point is the upper margin of the lateral end of the transverse process. Medially, the root of the transverse process expands rostrally along the neck of the superior articular process. Consequently, an electrode placed on the medial branch still lies behind the root of the transverse process and below its upper margin medially, as is evident both in dissections (Figure 3) and in lateral radi-



**Figure 3** Close-up views of an electrode with a 5-mm active tip placed parallel to and in contact with a right L4 medial branch (mb), viewed from the right. For clarity, the active tip of the electrode has been enhanced. A) The electrode lies in a deep position, with its distal tip near the origin of the medial branch and the other branches of the L4 dorsal ramus. B) The electrode has been withdrawn to lie opposite the middle of the neck of the superior articular process. Abbreviation: ZJ = zygapophysial joint.



**Figure 4** A declined view of an electrode parallel to, and in contact with, a right L4 medial branch. The nerve (mb) lies beside and slightly above the electrode (c.f. Figure 3A). The electrode runs across the neck of the superior articular process (sap) of L5. Abbreviations: TP = transverse process; iap = inferior articular process.

ographs (Figure 5). Lateral views show that the electrode is well short of the intervertebral foramen, even when placed in its deepest position (Figure 5A).

The L5 dorsal ramus is accessible for a substantial length of its course, where it crosses the ala of the sacrum (Figure 7). Electrodes can be placed deeply onto this nerve or in a more withdrawn position (Figure 8). In these positions, the electrodes assume characteristic appearances on radiographs.

In a declined view, the electrode crosses the ala of the sacrum, along the groove between the ala

and the root of the superior articular process of S1 (Figure 9). The nerve lies deep to the electrode in this groove.

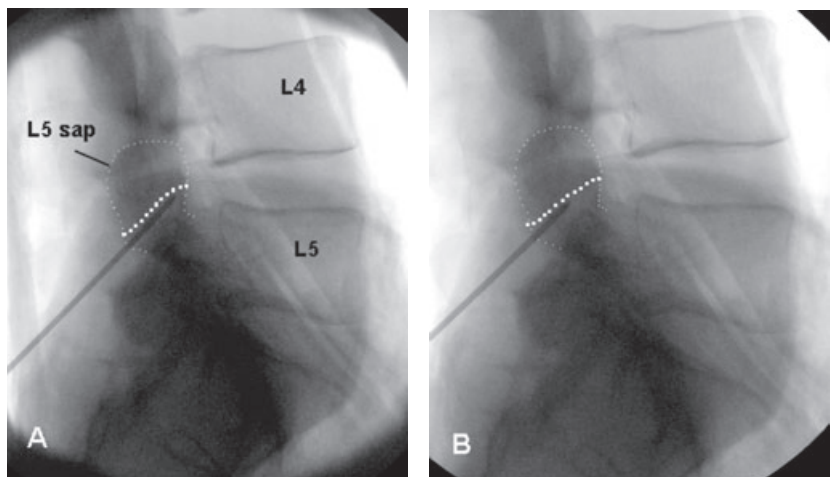
In a lateral view, the electrode crosses the neck of the superior articular process of S1 (Figure 10). In the fully inserted position (Figure 8A), the tip of the electrode lies opposite the junction of the anterior and middle thirds of the neck of the superior articular process (Figure 10A). In the withdrawn position (Figure 8B), the tip lies opposite the junction of the middle and posterior thirds of the neck (Figure 10B).

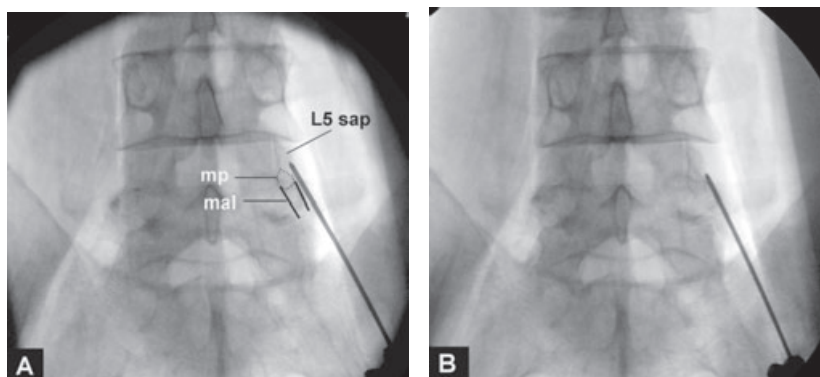
In an AP view, the electrode lies hard up against the lateral aspect of the S1 superior articular process (Figure 11). In the fully inserted position, its tip projects over the upper margin of the ala. In the withdrawn position, its tip lies opposite the caudal half of the L5-S1 zygapophysial joint.

If electrodes are placed parallel to, and in contact with, the target nerve, the lesions they make should incorporate the nerve. However, this requires that electrodes be accurately placed. If electrodes are not placed directly on the nerve, the risk is that the lesion made will fail to incorporate the nerve. The tolerable displacement from the nerve, before the lesion fails to incorporate the nerve, differs for different electrodes.


Figure 12 illustrates the sizes of lesions made with an SMK and an RRE electrode in relation to an L4 medial branch. It is evident that the SMK electrode, while in contact with the nerve, produces a lesion that encompasses the nerve; but there is little room for error (Figure 12A). The nerve is barely encompassed by the perimeter of the lesion. If the electrode were displaced by more than 1 mm from the nerve, the lesion made would

**Figure 5** Lateral radiographs of an electrode parallel to, and in contact with, a right L4 medial branch, whose course is indicated by the dotted line (c.f. Figure 3). The electrode crosses the neck of the superior articular process. A) The electrode lies in a deep position with its tip as far in as the origin of the medial branch. B) The active tip of the electrode has been withdrawn to lie opposite the middle of the neck of the superior articular process. Abbreviations: L4 = L4 vertebral body; L5 = L5 vertebral body; sap = superior articular process.





**Figure 6** Anteroposterior radiographs of an electrode parallel to and in contact with a right L4 medial branch (c.f. Figure 3). A) The electrode is in the deep position with its distal tip near the origin of the medial branch. B) the electrode has been withdrawn so that its tip lies opposite the middle of the neck of the superior articular process (sap). In both positions, the electrode lies hard up against the superior articular process, such that it lies medial to the lateral silhouette of the dorsal end of the superior articular process. The electrode passes about 20° oblique to the sagittal plane. This trajectory avoids the mamillo-accessory ligament (mal), which would be encountered along a parasagittal trajectory. Abbreviation: mp = mamillary process.



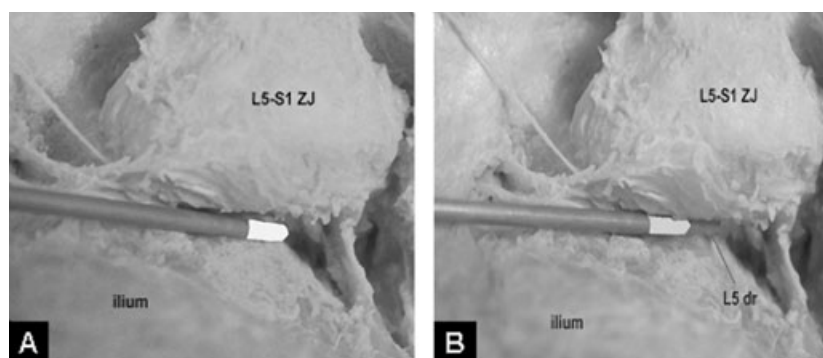
**Figure 7** A close-up view of a dissection of a right L5 dorsal ramus, viewed from the right, peering over the dorsal segment of the iliac crest. Abbreviations: ZJ = zygapophysial joint; dr = dorsal ramus; mb = medial branch; cb = communicating branch to S1 dorsal ramus.

fail to encompass the nerve. In contrast, the RRE electrode produces a wider lesion, which spreads well beyond the nerve when the electrode is in contact with it (Figure 12B). The electrode could be displaced by 2 mm from the nerve yet still encompass it.

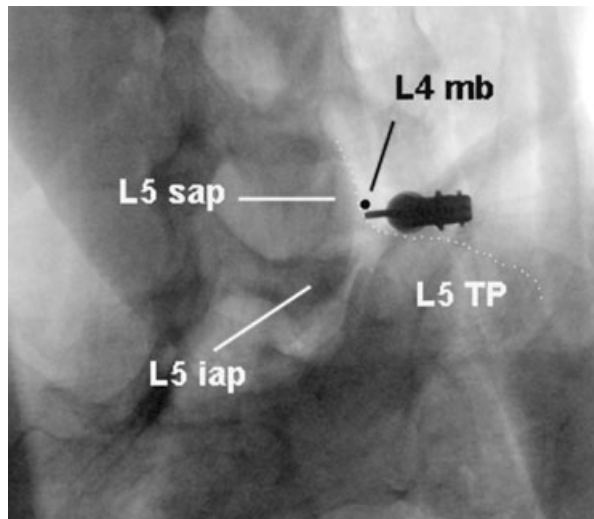
The same phenomenon can be depicted on radiographs (Figure 13). The lesion made by an SMK electrode extends only a relatively small distance laterally from the active tip (Figure 13A); whereas that of the RRE electrode covers a considerably larger territory (Figure 13B).

## Discussion

The original descriptions of the lumbar dorsal rami in the context of lumbar medial branch neurotomy described these nerves in terms of a



**Figure 8** Close-up views of an electrode placed parallel to, and in contact with, a right L5 dorsal ramus, viewed from the right, peering over the dorsal segment of the iliac crest. A) The electrode has been inserted deeply toward the upper margin of the ala of the sacrum. B) The electrode has been withdrawn to lie opposite the middle of the superior articular process of the sacrum. For clarity, the active tip of the electrode has been enhanced. Abbreviations: ZJ = zygapophysial joint; dr = dorsal ramus.

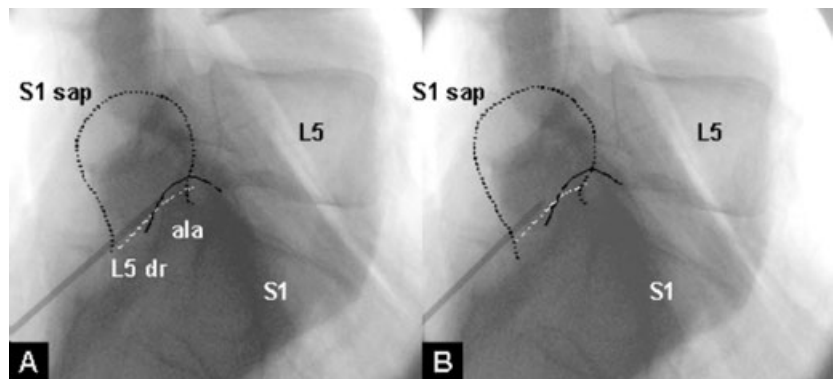


**Figure 9** A declined radiographic view of an electrode lying parallel to, and in contact with, a right L5 dorsal ramus (dr) (c.f. Figure 8). The nerve lies in the groove between the ala of the sacrum and the root of the S1 superior articular process (sap). Abbreviation: iap = inferior articular process.

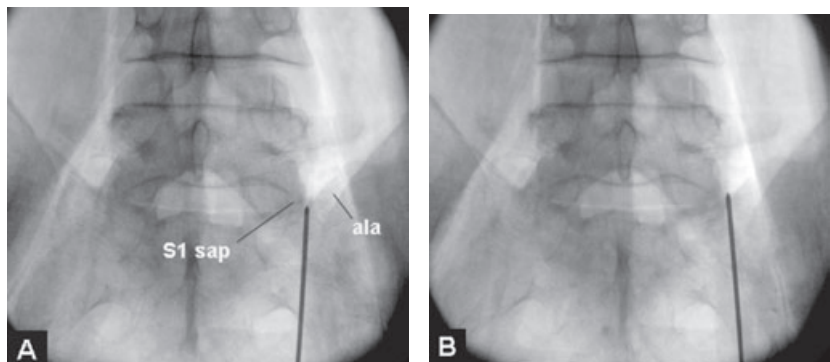
posterior view [6–9]. This was appropriate because, at the time, procedures such as lumbar medial branch block and lumbar medial branch neurotomy were performed from a posterior approach, often using a myelography table. As a result of this idiom, the medial branches of the lumbar dorsal rami were described as crossing the dorsal aspect of the root of the transverse process at its junction with the superior articular process [6–9].

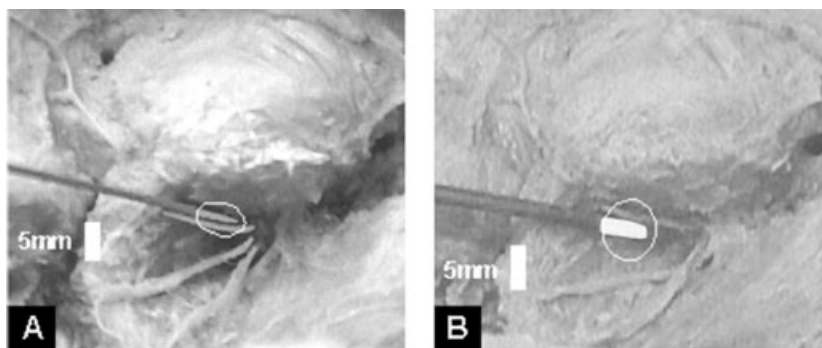
The greater availability and use of C-arm fluoroscopes allowed new views, such as oblique and lateral views, to be used for lumbar medial branch block and medial branch neurotomy. Consonant with this progression, the results of the present study modify the description of the medial branches of the lumbar dorsal rami. Rather than crossing the transverse process, the present study emphasizes that the medial branches run across the lateral aspect of the superior articular process. This difference in emphasis does not amend the anatomy, but alters the perception of it.

**Figure 10** Lateral radiographs of an electrode parallel to, and in contact with, a right L5 dorsal ramus (dr), which has been marked by a dotted line (c.f. Figure 8). A) The electrode has been inserted so that its tip lies near the top of the ala. B) The electrode has been withdrawn so that its tip lies opposite the middle of the superior articular process of S1 (S1 sap). Abbreviations: L5 = L5 vertebral body; S1 = S1 vertebral body.



**Figure 11** Anteroposterior radiographs of an electrode parallel to, and in contact with, a right L5 dorsal ramus (c.f. Figure 8). A) The electrode has been inserted so that its tip lies near the top of the ala of the sacrum. B) The electrode has been withdrawn so that its tip lies opposite the middle of the S1 superior articular process.





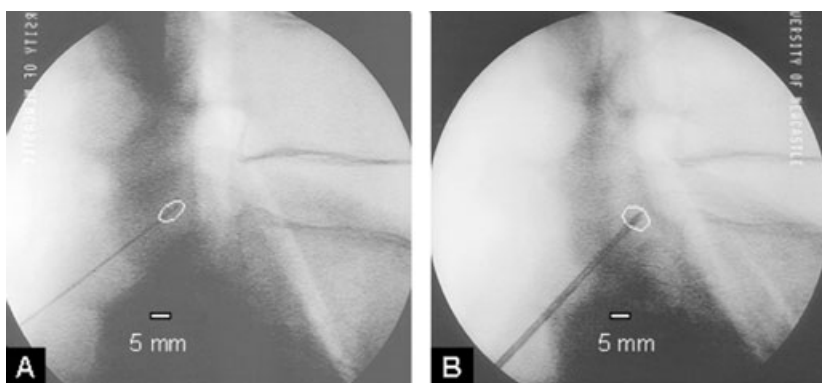
**Figure 12** Dissections of a right L4 medial branch with electrodes applied, around whose tips ellipses have been superimposed in order to indicate the mean size of the lesion that would be made. A) SMK electrode. The lesion barely encompasses the nerve. B) RRE electrode. The wider lesion readily encompasses the nerve and allows a margin of error in placing the electrode.

As long as operators perceived that the medial branch ran across the dorsal surface of the transverse process, they could be satisfied that electrodes placed directly ventrally, or obliquely, onto this surface would incur the medial branch. Under those conditions, an AP radiograph coupled with the sensation of bony resistance was enough to establish “correct” placement of electrodes.

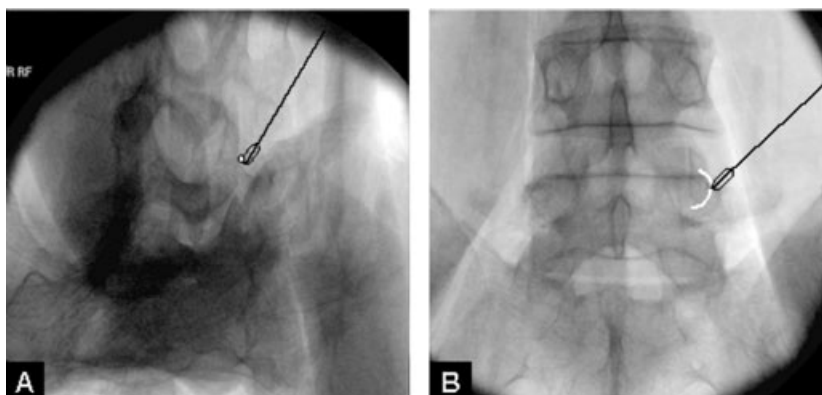
Such placements contravene the guideline that electrodes should be placed parallel to the target nerve. When electrodes are placed “end-on” against the nerve, most of the lesion produced lies

away from the nerve (Figure 14). Even if the tip of the electrode lies near, or even on, the nerve, because of the tapering shape of the lesion, the nerve may escape coagulation, or be only partially coagulated. Such placements, therefore, risk obtaining no relief, partial relief, or only short-lived relief. The less the target nerve is coagulated, the more rapidly it is likely to regenerate.

The present study demonstrates that, if an electrode is carefully placed parallel to the nerve, the lesion made will encompass a substantial length of the nerve. To achieve such placement, the elec-



**Figure 13** Lateral radiographs of electrodes in place on an L4 medial branch, around whose active tips ellipses have been drawn to illustrate the mean size of lesion made. A) SMK electrode. B) RRE electrode.



**Figure 14** Radiographs showing how lesions made perpendicular to the course of a medial branch may fail to encompass the nerve. A) Declined view. The medial branch is marked by a white dot. B) AP view. The medial branch is marked by a white line.



trode must be placed against the lateral surface of the neck of the superior articular process, which is where the nerve runs. Hence the emphasis in the present study in describing the medial branches as running across the neck of the superior articular process.

In the first instance, this placement is achieved by introducing the electrode along a declined view of the target level. That view is obtained by progressively tilting the X-ray beam caudally until the transverse process appears edge-on and the superior articular process is seen to rise cephalad from the transverse process. In that view, the medial branch runs across the lateral surface of the superior articular process at its neck, and that is where the electrode should be directed (Figure 9). Doing so achieves a placement of the electrode parallel to the nerve.

The depth of insertion is determined by a lateral view. For that reason, the dissections in the present study have depicted the target nerves in lateral view rather than the more conventional AP view. A lateral view shows the electrode crossing the neck of the superior articular process and shows how far the tip is from the intervertebral foramen (Figure 10). The present study indicates that the target zone for accurate medial branch neurotomy lies between the anterior quarter and the posterior quarter of the neck. Opposite the anterior quarter, the medial branch lies close to the other branches of the dorsal ramus (Figure 8). If these other branches are to be avoided, electrodes should not extend onto the anterior quarter of the neck. Opposite the posterior quarter, the medial branch is protected from coagulation by the mamillo-accessory ligament. Placing lesions in this area would be ineffectual and, therefore, superfluous.

An AP view should show the electrode snugly against the superior articular process, but also at an angle to the sagittal plane. The latter provision ensures that the electrode avoids the accessory process and mamillo-accessory ligament and reaches the target zone against the middle third of the neck of the superior articular process (Figure 10).

Similar considerations apply to the L5 dorsal ramus. This nerve presents a generous length along which it can be targeted. The effective target zone lies opposite the middle and posterior thirds of the neck of the S1 superior articular process (Figure 12). In order for the electrode to lie parallel to the target nerve, it needs to be inserted along a declined view that shows the groove between the ala and the superior articular process.

The objective is to place the electrode along this groove, which lodges the L5 dorsal ramus (Figure 11).

Also critical for the accurate conduct of lumbar medial branch neurotomy is an appreciation of the limited size of lesions made by various electrodes. On average, the maximum transverse dimension of a lesion is about two electrode-widths from the surface of the active tip. This means, in the case of SMK electrodes, whose diameter is only 0.7 mm, that the electrode must be placed within 1.4 mm of the nerve. In the case of RRE electrodes, the tolerance for displacement is 3.2 mm.

Operators who use large-diameter electrodes can be confident that the lesions that they produce will cover the target zone adequately. Those who use small-diameter electrodes have grounds for concern. They need to ensure that their electrodes lie exactly on the nerve. Whether or not preoperative electrical stimulation achieves this has not been demonstrated. Until this is demonstrated, it would seem wise to make multiple lesions with a small-diameter electrode in order to ensure that the area through which the nerve runs has been thoroughly coagulated.

The placements recommended in this study have been vindicated in observational, clinical studies. They have been shown to achieve good and lasting outcomes; and postoperative electromyographic studies have shown that the target nerves have been coagulated [13]. The same cannot be said of other variants of the procedure.

Perhaps curiously, the results of the present study are somewhat belated. They have demonstrated, after the fact, that placing electrodes across the neck of the superior articular process has a sound anatomical basis. Other variants of lumbar medial branch neurotomy have not been shown to have such a basis. Inaccurate technique, therefore, becomes the leading explanation of why variants of this procedure do not provide attractive, worthwhile, and compelling outcomes.

## References

- 1 Shealy CN. Technique for percutaneous spinal facet rhizotomy. Burlington, MA: Radionics; 1974.
- 2 Shealy CN. Facets in back and sciatic pain. A new approach to a major pain syndrome. *Minn Med* 1974;57:199–203.
- 3 Shealy CN. The role of the spinal facets in back and sciatic pain. *Headache* 1974;14:101–4.
- 4 Shealy CN. Percutaneous radiofrequency denervation of spinal facets. Treatment for chronic back pain and sciatica. *J Neurosurg* 1975;43:448–51.

- 5 Shealy CN. Facet denervation in the management of back and sciatic pain. *Clin Orthop* 1976;115:157-64.
- 6 Bogduk N, Long DM. The anatomy of the so-called "articular nerves" and their relationship to facet denervation in the treatment of low-back pain. *J Neurosurg* 1979;51:172-7.
- 7 Bogduk N, Long DM. Percutaneous lumbar medial branch neurotomy. A modification of facet denervation. *Spine* 1980;5:193-200.
- 8 Bogduk N, Wilson AS, Tynan W. The human lumbar dorsal rami. *J Anat* 1982;134:383-97.
- 9 Bogduk N. The innervation of the lumbar spine. *Spine* 1983;8:286-93.
- 10 Andersen KH, Mosdal C, Vaernet K. Percutaneous radiofrequency facet denervation in low-back and extremity pain. *Acta Neurochir (Wien)* 1987;87:48-51.
- 11 Cho J, Park YG, Chung SS. Percutaneous radiofrequency lumbar facet rhizotomy in mechanical low back pain syndrome. *Stereotact Funct Neurosurg* 1997;68:212-7.
- 12 Gallagher J, Petriccione di Valdo PL, Wedley JR, Hamann W, Ryan P, Chikanza I, Kirkham B, Price R, Watson MS, Grahame R, Wood S. Radiofrequency facet joint denervation in the treatment of low back pain: A prospective controlled double-blind study to assess its efficacy. *Pain Clinic* 1994;7:193-8.
- 13 Bogduk N, Macintosh J, Marsland A. Technical limitations to the efficacy of radiofrequency neurotomy for spinal pain. *Neurosurgery* 1987;20:529-35.
- 14 Dreyfuss P, Halbrosk B, Pauza K, Joshi A, McLarty J, Bogduk N. Efficacy and validity of radiofrequency neurotomy for chronic lumbar zygapophysial joint pain. *Spine* 2000;25:1270-7.
- 15 Leclaire R, Fortin L, Lambert R, Bergeron YM, Rossignol M. Radiofrequency facet joint denervation in the treatment of low back pain. A placebo-controlled clinical trial to assess efficacy. *Spine* 2001;26:1411-6; discussion 1417.
- 16 Koning HM, Mackie DP. Percutaneous radiofrequency facet denervation in low back pain. *Pain Clinic* 1994;7:199-204.
- 17 van Kleef M, Barendse GA, Kessels A, Voets HM, Weber WE, de Lange S. Randomized trial of radiofrequency lumbar facet denervation for chronic low back pain. *Spine* 1999;24:1937-42.
- 18 Jerosch J, Castro WH, Liljenqvist U. Percutaneous facet coagulation: Indication technique, results, and complications. *Neurosurg Clin N Am* 1996;7:119-34.
- 19 Wenger CC. Radiofrequency lesions for the treatment of spinal pain. *Pain Digest* 1998;8:1-16.
- 20 Deen HG, Fenton DS, Lamer TJ. Minimally invasive procedures for disorders of the lumbar spine. *Mayo Clin Proc* 2003;78:1249-56.
- 21 Lord SM, McDonald GJ, Bogduk N. Percutaneous radiofrequency neurotomy of the cervical medial branches: A validated treatment for cervical zygapophysial joint pain. *Neurosurg Q* 1998;8:288-308.
- 22 Bogduk N. The lumbar mamillo-accessory ligament. Its anatomical and neurosurgical significance. *Spine* 1981;6:162-7.
- 23 Lewin T, Moffett B, Viidik A. The morphology of the lumbar synovial intervertebral joints. *Acta Morphol Neerl Scand* 1962;4:299-319.