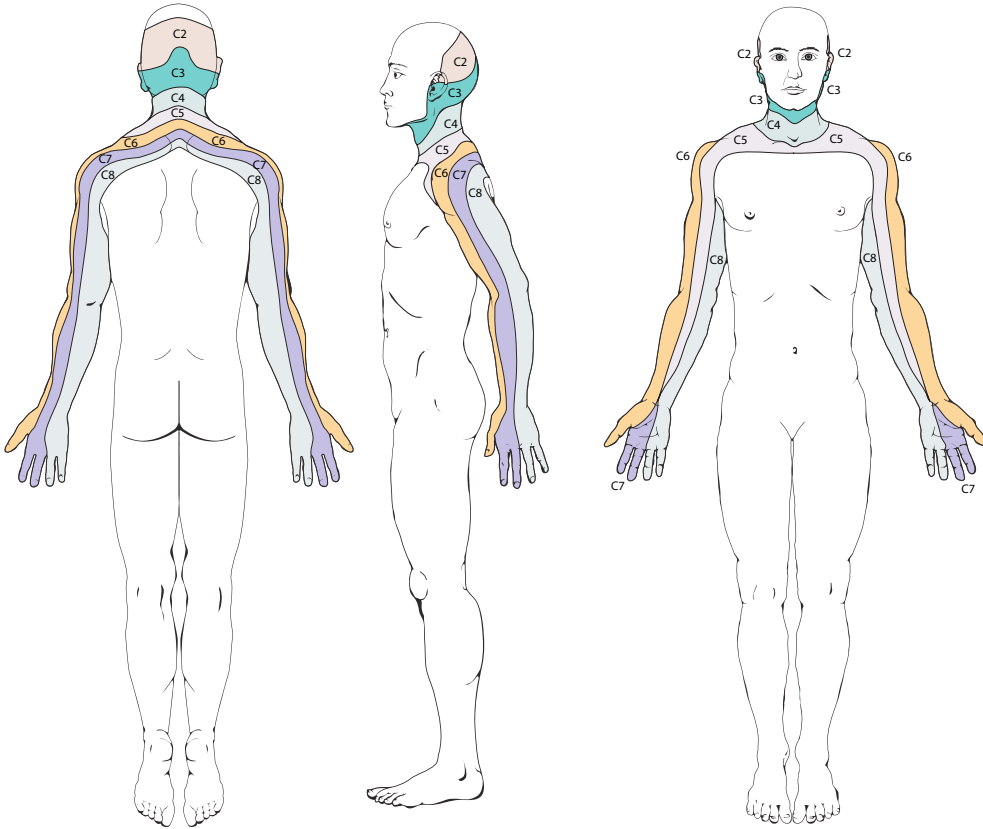
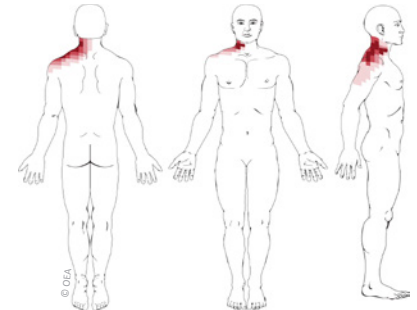


Cervical Radicular Pain Patterns

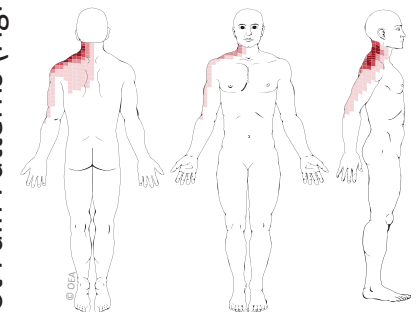


Cervical Dermatomes: Nerve Root Numbness Patterns (above)

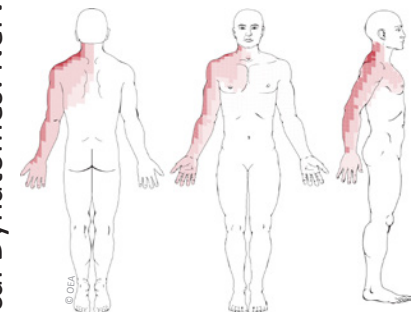
Based on: Slipman CW et al. Symptom provocation of fluoroscopically guided cervical nerve root stimulation. Are dynatomal maps identical to dermatomal maps? *Spine*. 1998;23:2235-42.



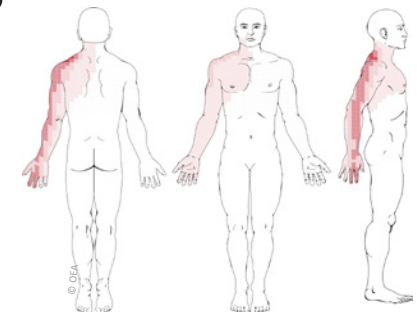
C4 Nerve Root Pain Pattern



C5 Nerve Root Pain Pattern

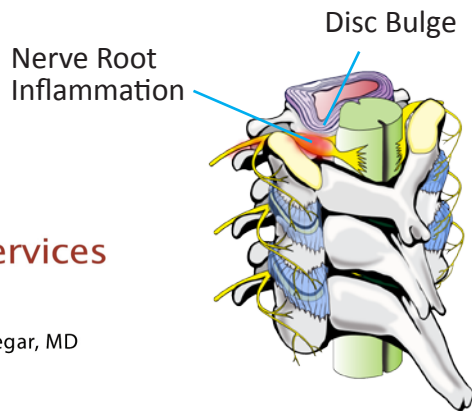


C6 Nerve Root Pain Pattern



C7 Nerve Root Pain Pattern

Cervical Dynatomes: Nerve Root Pain Patterns (right)



Integrated Health Services

MEDICAL CORPORATION

Eduardo E. Anguizola, MD & Hooman Rastegar, MD
Pain Management

714-543-2554