



OPEN ACCESS

Muscle biopsy: what and why and when?

Jon Walters,¹ Atik Baborie²

¹Neurology, Morriston Hospital, Swansea, UK
²Department of Cellular Pathology, University Hospital of Wales, Cardiff, UK

Correspondence to

Dr Jon Walters, Neurology, Morriston Hospital, Swansea SA6 6NL, UK; richard.walters@wales.nhs.uk

Accepted 30 April 2020

ABSTRACT

Skeletal muscle biopsy remains an important investigative tool in the diagnosis of a variety of muscle disorders. Traditionally, someone with a limb-girdle muscle weakness, myopathic changes on electrophysiology and raised serum creatine kinase (CK) would have a muscle biopsy. However, we are living through a genetics revolution, and so do all such patients still need a biopsy? When should we undertake a muscle biopsy in patients with a distal, scapulo-peroneal or other patterns of muscle weakness? When should patients with myositis, rhabdomyolysis, myalgia, hyperCKaemia or a drug-related myopathy have a muscle biopsy? What does normal muscle histology look like and what changes occur in neurogenic and myopathic disorders? As with Kipling's six honest serving men, we hope that by addressing these issues we can all become more confident about when to request a muscle biopsy and develop clearer insights into muscle pathology.

INTRODUCTION

Before considering when you might request a muscle biopsy, it is worth considering how a biopsy is done and what can be learnt from it. Having an understanding of muscle pathology enables us to communicate with pathology colleagues and, when results are available, to translate muscle biopsy results for our patients' benefit. We already recognise how such a similar investment helps our discussions with neuroradiology colleagues.

What is a muscle biopsy?

Muscle biopsy can be either open or closed (needle or punch) and both have their champions. A closed biopsy has the advantages of being more cosmetically appealing, minimally invasive and potentially yielding more than one specimen. The small sample size, however, creates challenges with handling and orientation; if pathology is patchy it may be missed.

An open biopsy is more invasive, but the operator can see the muscle, avoid

tendinous insertions and can obtain an adequate specimen for biochemical studies, which is potentially important in mitochondrial disease, as we shall see. The person taking the biopsy needs adequate experience, skill and interest. In adult practice, open biopsy is generally favoured.

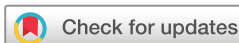An open biopsy is undertaken in a sterile operating theatre. The skin and subcutaneous tissue are infiltrated with a local anaesthetic, avoiding the muscle. The incision is 4–6 cm along the long axis of the limb. The skin, subcutaneous fat and fascia overlying the muscle are dissected, and the biopsy is taken with muscle fibre fascicles running longitudinally. Complications are rare but include infection, delayed haematoma formation, muscle herniation through fascial defect and wound dehiscence.

The biopsy, usually about 15 × 10 × 5 mm in size, is laid on a non-absorbent card in a dry specimen container. The principle is to 'snap freeze' the muscle in isopentane cooled by liquid nitrogen (to approximately –160°C). This renders the sample in as life-like a state as possible without using a chemical fixative. 'Snap freezing' allows the tissue to be cut for diagnostic investigations and prevents the damage caused by formalin fixation or ice crystal formation (slow freezing) (contrast figures 1 with 2).

Which muscles should be biopsied?

Select a muscle that is weak but can overcome gravity. Very weak muscles show marked loss of muscle fibres with fatty or connective tissue replacement and reveal no remnant of the underlying disease process: an 'end-stage' biopsy. Avoid muscles that have been injured, injected or sampled by neurophysiology within 6 months, as these situations can result in finding misleading inflammation.

A limited number of muscles are biopsied: in the upper limb, biceps brachii or deltoid; in the lower limb, quadriceps



© Author(s) (or their employer(s)) 2020. Re-use permitted under CC BY-NC. No commercial re-use. See rights and permissions. Published by BMJ.

To cite: Walters J, Baborie A. *Pract Neurol* 2020;**20**:385–395.




Figure 1 Normal adult skeletal muscle: subsarcolemmal located nuclei, average fibre size about 40–80 μm , surrounded by sparse endomysial connective tissue and visible perimysial septae (H&E stain, $\times 100$).

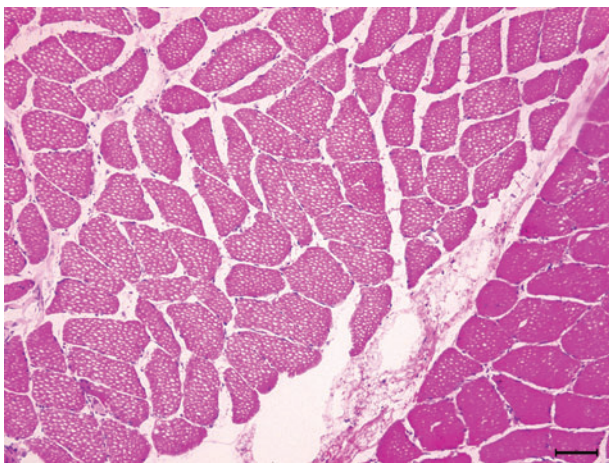


Figure 2 Freezing artefacts: fine sarcoplasmic holes (caused by ice crystals) prevent examination of fibres (H&E, $\times 100$).

femoris (vastus lateralis or rectus femoris) or gastrocnemius. The pathologist needs to know what these muscles look like when healthy. Fibre-type composition and the normal range of fibre size will vary between muscles, depending upon their functional role. If contemplating using another muscle, consult with pathology colleagues.

Timely communication with the person undertaking the biopsy and pathologist is key, including clinical details and our diagnostic suspicions.

What does normal muscle look like?

A transverse section of normal muscle reveals fibres of roughly the same size, each comprising hundreds of myofibrils. The intermyofibrillar network sits between the myofibrils, composed of sarcoplasm, mitochondria and sarcoplasmic reticulum with the

transverse tubular system. Nuclei occupy the periphery of the fibres (figure 1).

Each fibre is roughly polygonal transversely and packed snugly alongside its neighbours, with the endomysium squeezed between adjacent fibres. Perimysium binds groups of fibres together, and the fascicles are collected together within the muscle belly, wrapped by the epimysium.

What changes do you see in denervated muscle?

Muscle fibres that have lost their nerve supply atrophy and become small angulated remnants, squeezed between their normal-sized, innervated neighbours. Denervated muscle fibres attract nerve twigs from healthy neighbours; the nerve twig sprouts and reinnervates the neurone-deprived myofibre. The reinnervated fibre assumes the same identity (type 1 or type 2 fibre) as its neighbour, since the reinnervating anterior horn cell exclusively innervates either type 1 or type 2 fibres. Reinnervated neighbouring muscle fibres, therefore, assume the same identity, and the normal mosaic distribution of fibre types becomes distorted into sheets of neighbouring fibres that are all the same type (fibre-type grouping).

What sort of changes do you see in myopathies?

In many myopathies, muscle fibre size is no longer uniform, and instead, there is considerable fibre size variation. Large fibres may split, particularly in muscle dystrophies. Nuclei, usually situated peripherally, start to migrate centrally.

Type 1 and 2 fibres may be selectively involved in some myopathies and in other health conditions. Type 2 fibre atrophy, for instance, typically occurs during immobility, corticosteroid use or general ill health. Type 1 atrophy occurs in some congenital myopathies; type 1 fibres tend to be more numerous than type 2 in congenital myopathies.

In many myopathies, the intermyofibrillar network changes appearance, becoming ‘moth-eaten’ and losing its characteristic regular cytoarchitecture.

The modified Gömöri-trichrome stain may show inclusions within muscle fibres, including the rod-like bodies in nemaline myopathy, or the darkly staining accumulation of myofibrillar material characteristic of myofibrillar myopathies (figures 3 and 4). In the core myopathies, oxidative stains such as nicotinamide adenine dinucleotide dehydrogenase (NADH)-TR may show well-demarcated areas of reduced or absent staining within the sarcoplasm (figure 5).

The endomysium becomes thickened and fibrotic in some muscle diseases and is particularly striking in muscle dystrophies (figure 6).

Inflammatory changes may develop in the endomysium of the inflammatory myopathies; immunohistochemistry can identify the types of inflammatory cell present (table 2). Immunohistochemistry can also identify the major histocompatibility antigen 1 (MHC1) on

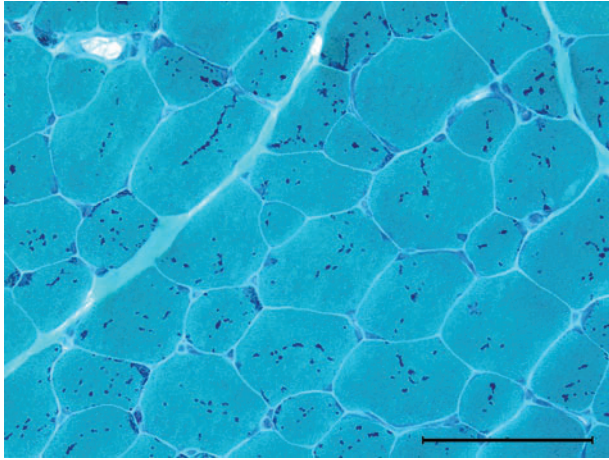


Figure 3 Nemaline myopathy: rod or granular red sarcoplasmic inclusions (Gömöri-trichrome stain $\times 400$).

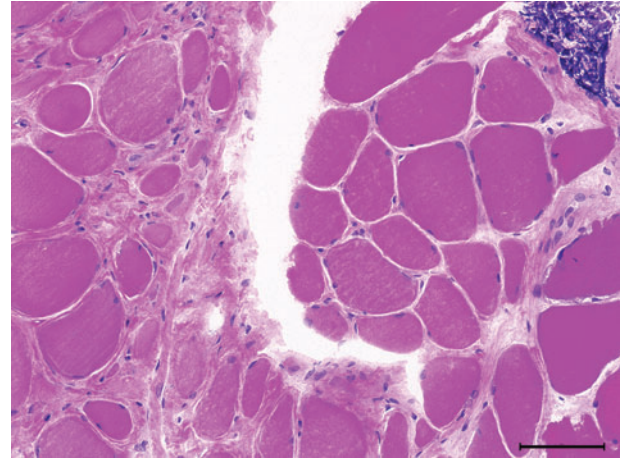


Figure 6 Limb-girdle muscular dystrophy: marked fibre atrophy, increased endomysial connective tissue suggesting dystrophy. A focus of lymphocytic infiltrate (top right corner) as sometimes seen in LGMD2B (H&E, $\times 200$).

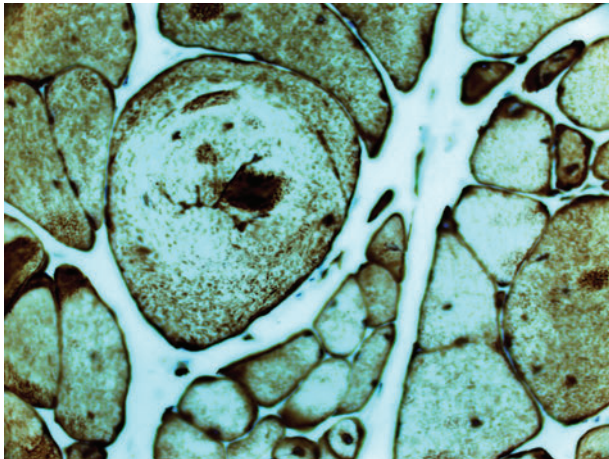


Figure 4 Myofibrillar myopathy showing marked fibre size variation, cytoplasmic inclusions and splitting fibres; desmin accumulation (desmin immunohistochemistry $\times 200$).

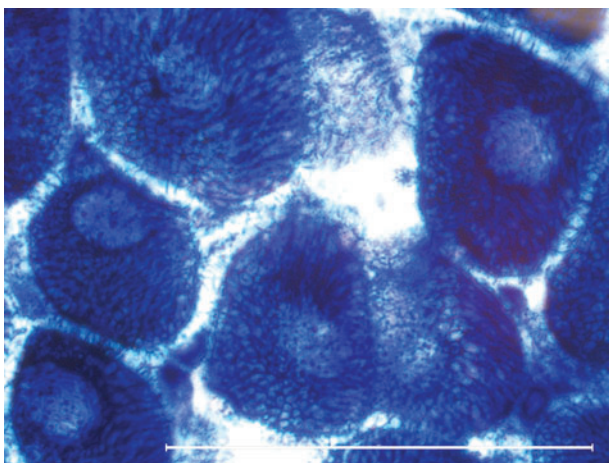


Figure 5 Central cores: pale cores lacking in enzyme activity (nicotinamide adenine dinucleotide dehydrogenase stain).

the sarcolemma in inflammatory myopathies or the membrane-attack complex deposit on the capillary endothelium in dermatomyositis. Inflammatory changes occasionally occur in genetic muscle diseases, including facioscapulohumeral dystrophy and dysferlinopathies (LGMD2B).

Western blot or immunoblot is a technique that uses gel electrophoresis to separate individual proteins from a mixture of proteins, according to their weight. Patients with Becker muscular dystrophy may have normal immunochemistry if the available antibodies happen to bind to the preserved parts of the dystrophin protein. Becker patients with smaller (80%) weight dystrophin on western blot have a genetic deletion, whereas those with a larger (5%) weight dystrophin have a duplication; the remainder have less of the normally sized dystrophin (15%).

No single pathological feature should be considered in isolation. Vacuoles in muscle fibres develop in some toxic myopathies, inclusion body myositis and some genetic myopathies. Focussing only on vacuoles might easily lead to mistaking a hydroxychloroquine-induced toxic myopathy for Pompe's disease, since both have vacuoles.¹ As the unassuming Miss Marple said, 'One must provide an explanation for everything. Each thing has to be explained away satisfactorily. If you have a theory that fits every fact—well, then, it must be the right one'.

What stains are commonly used on muscle biopsy specimens and what do they tell us?

Tables 1 and 2 set out some of the stains commonly used and their contributions to understanding muscle physiology and pathology. In immunocytochemistry, the muscle biopsy is incubated with an antibody that is directed against a particular antigen.

Table 1 Histology and histochemistry used on muscle biopsies

Shows general morphology— fibre size, any central nuclei, inflammatory cells, connective tissue, split fibres, inclusions	
H&E	
Myosin or adenosine triphosphatase (ATPase) at acidic and alkaline pH 4.3, 4.6, 9.4	Highlights type 1 fibres (slow/oxidative/fatigue resistant) and type 2 fibres (fast/glycolytic/fatigue prone). These are randomly distributed throughout a normal biopsy—a mosaic pattern
Oxidative stains—for instance reduced nicotinamide adenine dinucleotide dehydrogenase	Helps to look at the intermyofibrillar network, mitochondrial content and fibre-type distribution
Other oxidative stains cytochrome oxidase (COX) and succinate dehydrogenase	Mitochondrial disease—COX-negative fibres and ragged-blue fibres—see text, figures 7, 8 and 9 .
Hydrolytic enzymes— Acid phosphatase	Acid phosphatase—vacuoles, macrophages and lysosomes—see acid maltase deficiency below
Alkaline phosphatase	Alkaline phosphatase—perimysial staining in immune-mediated myopathies, such as antisignal recognition particle necrotising myopathy, rarely in dystrophies or inclusion body myositis.
Storage material— Periodic acid-Schiff (PAS)— glycogen	For instance, acid maltase deficiency—a lysosomal enzyme abnormality—shows PAS-positive and acid phosphatase reflecting glycogen accumulation and the lysosomal origin of the vacuoles.
Oil red O or Sudan black—lipids	Lipid generally accumulates lipid metabolic disorders with static symptoms (chronic myopathy with fixed weakness)—primary carnitine deficiency, multiple acyl-coenzyme A dehydrogenase deficiency and neutral lipid storage disease.
Others include— Myophosphorylase enzyme	McArdle’s disease (glycogen storage disease type V)
Phosphofructokinase	Glycogen storage disease type VII

In limb-girdle muscular dystrophies 2A and 2I, no immunocytochemical stain is invariably abnormal. Furthermore, since proteins interact with each other, there can be secondary immunocytochemical changes. For example, the transmembrane sarcoglycan complex links to the ‘C’ region of dystrophin; an abnormality in one sarcoglycan protein may disrupt its fellow sarcoglycans as well as dystrophin (all for one and one for all).^{2,3}

Electron microscopy often provides further information, including identifying filamentous inclusions in inclusion body myositis or various abnormalities in

congenital myopathies. Electron microscopy led to the discovery that mitochondria have their own DNA and that people with mitochondrial diseases have visible paracrystalline ‘parking lot’ inclusions within their mitochondria.⁴

When to request a muscle biopsy in a patient with suspected muscle weakness?

Investigating potentially myopathic weakness often requires consideration of a muscle biopsy. The practical neurologist aims to narrow the differential diagnosis clinically before embarking on investigations. There are many clues to help to distinguish between an acquired myopathy and genetic disorder, see further reading.^{35–7}

Several myopathies may then become recognisable (or almost recognisable) at the bedside, and so the next diagnostic step might be a genetic or other blood test, rather than a muscle biopsy ([table 3](#)).

Gestalt impressions are vital in endocrine-related myopathies, confirmed with appropriate biochemical investigations ([table 3](#)). A muscle biopsy might still be necessary if there is no improvement despite restoring a normal hormonal milieu.

There are six patterns of weakness commonly referred to in muscle diseases; we look at each in turn and provide some guidance about the role of muscle biopsy in each. For the sake of this discussion, we have combined distal and scapulo-peroneal forms.

Limb-girdle weakness

Generally, in a patient with a likely genetic cause for limb-girdle weakness, especially with pseudohypertrophy and raised serum creatine kinase, we request a dried blood spot test for α -glucosidase, and genetic testing for dystrophinopathy and LGMD2I, before a muscle biopsy.^{5,6,8} The clinical rules distinguishing genetic and acquired myopathies are robust but fallible, one reason to favour biopsy at this point.

However, practice varies, and some neurologists use next-generation sequencing before muscle biopsy. A muscle biopsy and next-generation sequencing are not mutually exclusive; patients often need both. Whole-exome sequencing, for instance, may identify large numbers of potential pathogenic variants. A muscle biopsy can help to identify an ‘in-depth phenotype’, steering us towards the culprit gene that is known to produce the particular muscle pathology.^{9,10}

Distal or scapulo-peroneal patterns of weakness

Muscle conditions with distal or scapulo-peroneal patterns of weakness are also sometimes recognisable at the bedside ([table 3](#)). Myofibrillar or rimmed vacuoles are to be expected, but there may be other less common pathology; this favours an early biopsy rather than a narrower ‘phenotype-driven’ gene panel approach. For example, Cori–Forbes disease with its characteristic pools of subsarcolemmal glycogen can present with distal weakness.^{3,7,11}

Table 2 Examples of immunohistochemistry

Dystrophin—there are three commonly used antibodies to dystrophin—Dys-1 (binds to the rod), Dys-2 (binds to the C-terminal) and Dys-3 (binds to the N-terminal)	Duchenne muscular dystrophy Becker muscular dystrophy
Spectrin	Used to assess membrane integrity—important for accurate interpretation of, for instance, dystrophin staining
Myotilin	LGMD1A
Caveolin-3	LGMD1C
Dysferlin	LGMD2B
Sarcoglycan	LGMD2C–F
Major histocompatibility complex class I—upregulation on sarcolemma CD68 (macrophage), CD20 (B cells) or CD8 (cytotoxic T cell), CD4 (T helper cells and dendritic cells). Membrane-attack complex deposit seen on capillary endothelium in dermatomyositis	Inflammatory myositis—helps identify a myositis and to distinguish between dermatomyositis, overlap myositis, polymyositis, inclusion body myositis and necrotising autoimmune myopathy.
Demonstrate inclusions—for example TDP-43, p62, tau, amyloid	Seen in inclusion body myositis
Desmin, myotilin, gelsolin, β -amyloid precursor protein and other proteins	Seen in myofibrillar myopathies

Table 3 Some myopathies that may not require a biopsy for diagnosis

Myotonic dystrophy—DM1 is recognisable—genetic test
Dermatomyositis and other inflammatory myopathies—some diagnosed by myositis-specific and myositis-associated antibodies in the appropriate clinical setting
Inclusion body myositis is recognisable at the bedside, but we strongly recommend considering a biopsy
Some forms of rhabdomyolysis—note: wait 8 weeks if considering a biopsy—see text
▶ Use the acronym 'RHABDO' to identify those in whom biopsy might help the diagnosis (see box 1)
▶ Exertional rhabdomyolysis—consider metabolic myopathies and also glycogen and lipid disorders (and mimics)—possible metabolic gene panel rather than a biopsy
▶ Non-exertional non-traumatic includes statin users co-prescribed medication that interferes with statin metabolism—often no need for biopsy
Endocrine causes—recognisable at bedside and next test is obviously to confirm clinical impression—for example
▶ Dysthyroid
▶ Cushing's syndrome
▶ Addison's disease
Oculopharyngeal muscular dystrophy—genetic test
Non-dystrophic myotonias. Myotonia congenita might be recognised quickly with genetic test as the next step; the others may require electrophysiology (short exercise test) and genetics
Periodic paralysis—electrophysiology (long exercise test) and genetic tests
Rippling muscle disease—genetic test, although sometimes occurs in an acquired form in myasthenia
Emery–Dreifuss syndrome and other contracture myopathies, for example, Bethlem myopathy, rigid-spine syndrome—MR imaging of muscle and genetic tests often before biopsy.
Facioscapulohumeral dystrophy—scapuloperoneal weakness—genetic test
Pseudohypertrophy myopathies—often Becker or LGMD2I (and dried blood test for α -glucosidase deficiency)—before biopsy
Myopathy with early respiratory muscle weakness—think Pompe's disease (acid maltase deficiency)—dried blood test for α -glucosidase deficiency before other genetic tests or biopsy.
Mitochondrial disorders—often progressive external ophthalmoplegia—test <i>POLG</i> gene in blood and A3243G in urine but if negative then a muscle biopsy

Distal arm and proximal leg weakness

This pattern raises suspicion of inclusion body myositis, although myotonic dystrophy type 2 (DM2) can have a similar distribution of weakness. We have a low threshold for testing for DM2, particularly if there are familial cataracts.

We recommend a biopsy to confirm inclusion body myositis and to exclude granulomatous myositis, which has a similar distribution of weakness but, unlike inclusion body myositis, may respond to immunosuppression.

Light microscopy in inclusion body myositis should show endomyseal inflammation, cytotoxic T cells partially invading non-necrotic muscle fibres and rimmed vacuoles. All three features are not always present; rimmed vacuoles may be a late feature. There are often mitochondrial abnormalities including COX-negative fibres or ragged-red fibres (see below). Electron microscopy shows 15 nm tubulofilamentous inclusions in the cytoplasm or nucleus, and immunohistochemistry may identify 'Alzheimer-characteristic proteins' such as

hyperphosphorylated tau. Finding partial invasion and mitochondrial abnormalities is particularly supportive of a clinical diagnosis of inclusion body myositis.¹²

Progressive external ophthalmoplegia and/or ptosis

It is worth considering myasthenia, dysthyroid eye disease or oculopharyngeal muscular dystrophy, which do not require a muscle biopsy. Mitochondrial disorders then form the majority of the remaining patients.

We look for two common genetic causes of mitochondrial disease, the A3243G mutation in the mitochondrial genome (mtDNA) in a urine sample and *POLG*, a nuclear gene encoding the catalytic subunit of DNA polymerase gamma, detectable in leucocyte DNA. Polymerase gamma is one of several nuclear genes required to maintain healthy mtDNA; *POLG* mutations cause secondary mtDNA mutations that accumulate with age.⁷

If these are negative, we undertake a muscle biopsy from quadriceps or deltoid; levator palpebrae or orbicularis oculi biopsies are potentially rich in pathology, but limb muscles seem to be adequate.

Cytochrome c oxidase (COX, complex IV) histochemistry is centre stage when assessing adults with suspected mitochondrial disease. It reflects complex IV activity in the respiratory chain, and three of its subunits are mitochondrial DNA encoded, see figure 7.

There are multiple copies of mtDNA within each cell—the myofibre in skeletal muscle. Most frequently, mtDNA mutations affect only a proportion of mitochondria within each myofibre, termed heteroplasmy, and the fraction varies widely between myofibres.

Patients with mtDNA mutations, who account for approximately two-thirds of adult mitochondrial cases,

therefore have a mosaic of ‘COX-negative’ fibres reflecting differences in heteroplasmy between myofibres. Myofibres with higher heteroplasmy tend to be COX negative. The remaining third of adult mitochondrial patients have nuclear DNA abnormalities and often a more uniform reduction in COX staining, with secondary mtDNA abnormalities globally affecting all myofibres.^{7,13}

COX-negative fibres are best demonstrated by serially staining for COX, followed by complex II (succinate dehydrogenase). Succinate dehydrogenase is entirely encoded by nuclear genes and therefore maintains normal activity irrespective of heteroplasmy levels, see figures 7 and 8.

Myofibres with higher heteroplasmy may also show compensatory mitochondrial proliferation—the ‘ragged’ part in ragged-red or ragged-blue fibres (figures 8 and 9).

It is worth knowing that the A3243G mutation, the most common cause of mitochondrial disease, can have surprisingly well-preserved COX staining. A useful clue in this circumstance is the strong succinate dehydrogenase staining visible in the blood vessel walls of muscle.^{7,14,15}

When histochemical clues are not forthcoming but suspicion remains, then respiratory chain enzyme analysis and/or quadruple immunofluorescence that quantifies complex I and IV in the muscle biopsy can help identify abnormalities.^{15–17}

Muscle is also the gold standard tissue for examining mtDNA.¹⁸ In tissues with high replication rates, such as blood, heteroplasmy tends to decrease with age. Dividing cells with higher heteroplasmy may be ‘weeded out’ as they are at an ‘evolutionary’ disadvantage. Detecting the A3243G in a blood sample,

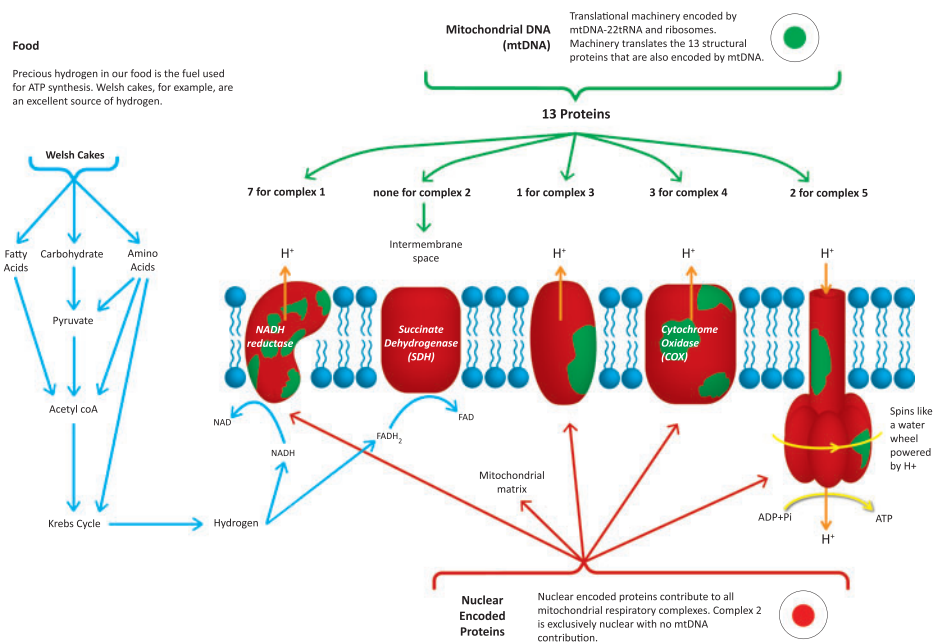


Figure 7 Mitochondria—both mtDNA and nuclear DNA contribute to the respiratory complexes. Nuclear encoded proteins are red and mtDNA-encoded proteins are green. Note complex II is made exclusively from nuclear encoded proteins.

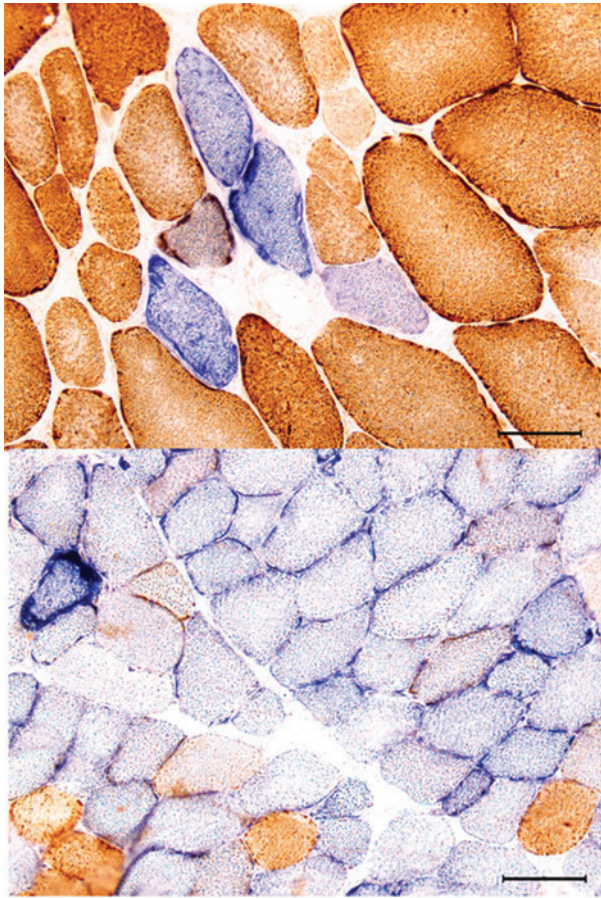


Figure 8 (A) COX-negative fibres take up the blue SDH stain but not the brown COX stain. The fibres should all stain brown, but fibres with higher levels of mitochondrial heteroplasmy appear blue among a sea of more normal brown fibres (COX-SDH stain). (B) Many COX-negative fibres and a ragged-blue fibre (left upper margin), evidence of a compensatory proliferation of mitochondria within a struggling myofibre. COX, cytochrome oxidase; SDH, succinate dehydrogenase.

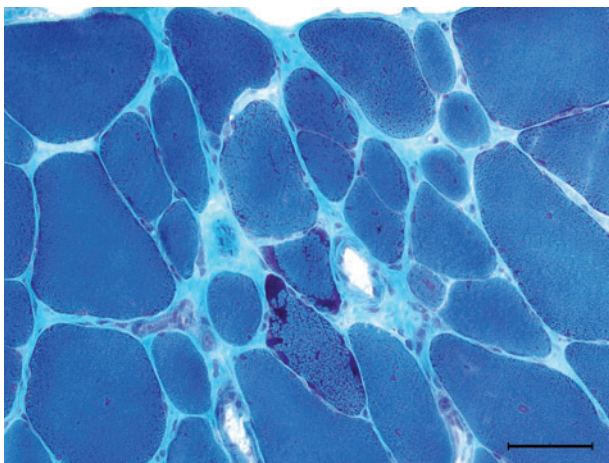


Figure 9 Ragged-red fibres, like ragged-blue succinate dehydrogenase stain, reveal mitochondrial proliferation in struggling myofibres (Gömöri-trichrome staining).

therefore, declines with age, although it remains detectable in urinary epithelial cells.¹⁹ In postmitotic muscle, heteroplasmy remains stable or increases; for instance, mtDNA with a deletion might replicate faster than wild-type mtDNA. Our postmitotic skeletal muscle is therefore ideal for mtDNA genetic analysis.

It is a privilege to grow old with our mitochondria, but as we do so it is worth remembering that the proportion of COX-negative myofibres increases, to up to 5% over 50.²⁰

Neck extensor weakness

We avoid biopsy of neck extensor muscles, as their normal histology is not well characterised. If weakness remains isolated to neck extensors, then we consider a period of 3–6 months of immunosuppression as a subset of patients with isolated neck extensor myopathy can respond.

Isolated neck extensor myopathy, myasthenia gravis (including antimuscle-specific kinase, MuSK antibodies) and motor neurone disease are the three most common disorders that may present with isolated or predominant neck extension weakness. Hyperthyroid and hyperparathyroid myopathies may also present like this.

Myotonic dystrophy, Pompe's disease and facioscapulohumeral dystrophy may also develop neck extension weakness but frequently in advanced stages with weakness elsewhere including concurrent neck flexion weakness. These disorders require electrophysiology, serology and other blood tests but none generally requires a muscle biopsy.²¹

What if we suspect myositis?

We biopsy a weak muscle that can overcome gravity when we suspect an idiopathic inflammatory myopathy in the vast majority of cases. We simultaneously look for myositis-specific and myositis-associated antibodies. Myositis-specific antibody is not invariably present (about 60% of dermatomyositis cases) but provide additional insights into the likelihood of comorbidities, such as malignancy or interstitial lung disease, and likely response to treatment.²²

Very occasionally false-negative biopsies do occur, since pathology can be patchy. In this situation, we organise MRI to highlight muscle oedema and pathology, revealed as high-signal intensity on short tau inversion recovery sequences to guide us to a biopsy site.²³

Occasionally, if there are clear clinical clues, such as a typical dermatomyositis rash and only mild weakness, we rely solely on antibody testing initially without a biopsy, see case 1.

What is the role of biopsy in patients who have had rhabdomyolysis?

The acronym 'RHABDO' is a useful prompt to help identify those patients who may require further investigation, possibly including a biopsy (box 1).^{24 25} Delay

Box 1 Rhabdo stands for

- ▶ R—Recurrent episodes of exertional rhabdomyolysis
- ▶ H—HyperCKaemia more than 8 weeks after event
- ▶ A—Accustomed to exercise
- ▶ B—Blood creatine kinase (CK) concentration above 50× upper limit of normal
- ▶ D—Drug ingestion insufficient to explain exertional rhabdomyolysis
- ▶ O—Other family members affected or other exertional symptoms

the muscle biopsy for about 8 weeks following rhabdomyolysis, otherwise the overwhelming destruction will dwarf and obscure other diagnostic features.

The causes of rhabdomyolysis are categorised as traumatic, non-traumatic exertional and non-traumatic non-exertional.

The non-traumatic exertional group includes the metabolic myopathies. Their workup often includes a gene panel for rhabdomyolysis and metabolic disorders—their clinical features are described elsewhere (see further reading).^{24 26} Some myopathies that cause non-traumatic exertional rhabdomyolysis are not included in such a panel, for example, muscle dystrophies (case 2), ryanodine receptor myopathies and mitochondrial disorders.^{27–29} Clinicians should seek relevant clinical clues when reviewing patients following their crisis. The indications for biopsy in these circumstances will then be similar to those when suspecting a dystrophy or a mitochondrial disorder (outlined above).

Rhabdomyolysis precipitated in someone taking statins when given medication that interferes with statin breakdown does not require a biopsy. However, a biopsy may be appropriate for someone taking statins who develops a suspected immune-mediated necrotising myopathy; such a complication can occur months to years after starting statins (see further reading).

What is the role of biopsy in patients with hyperCKaemia?

If a patient's serum CK has been high, then repeat the test after refraining from exercise for a week. Interpretation requires flexibility; the heavyweight champion of the world will probably have a serum CK beyond the upper limit of normal.³⁰

Drugs, endocrine, metabolic problems as well as macro CK can all raise the serum CK concentration. After considering these, many neurologists then proceed to electrophysiology and a possible biopsy. Next-generation sequencing can play a role, but once again, biopsy is often required for a 'deep phenotype' to help interpret the genetic tests.⁹

A diagnosis is more likely if electrophysiology shows myopathic changes, if the patient is young (<25 years), or if the serum CK is over three times the upper limit of

normal. We tend to consider performing a muscle biopsy when a patient has one or more of these.³¹ We warn patients that the chances of a diagnosis are only about 1 in 4. These diagnoses may include metabolic myopathies, dystrophinopathies, limb-girdle muscular dystrophies and inflammatory myopathies.^{32 33}

When should we consider a biopsy for a potential drug-related muscle complication?

Table 4 summarises some of the medications that have provoked muscle problems that we have encountered recently. We consider a muscle biopsy if there is no improvement 3–6 months after drug withdrawal, but sooner if the patient worsens.^{34–36} We might also consider a biopsy if there are several competing narratives. For example, consider a patient with a renal transplant and underlying connective tissue disorder who develops a gradually progressive proximal weakness. Is it the corticosteroid, the colchicine or the statin? Could it be a myositis? Muscle biopsy can help; vacuolar changes without inflammation would, for example, incriminate colchicine.

What is the role of biopsy in patients with myalgia?

Muscle pain is a near-universal experience. For instance, it accompanies infections ranging from chikungunya (meaning 'to become contorted' in Kimakonde) through to humdrum colds and 'influenza.

Clinical criteria define conditions like fibromyalgia and chronic fatigue. They are 'bread and butter' for our primary care colleagues and expertly managed by them.

The following might prompt further investigations:

Table 4 Iatrogenic myopathies witnessed in muscle clinic over the last few years

Drugs and myalgia

Statins—with or without raised serum creatine kinase

Calcium channel blockers

Corticosteroid and selective serotonin reuptake inhibitor (SSRI) withdrawal

Nitrofurantoin and ciprofloxacin

Aromatase inhibitors—medical treatment for breast cancer

Colchicine

Drugs and inflammatory myositis

Statins

Immune checkpoint inhibitors—immune-related adverse events (irAE)

Drugs and rhabdomyolysis

Heroin, cocaine, alcohol and amphetamine

Statins

Other

Acute quadriplegic myopathy (critical care myopathy) including one patient who had a striking external ophthalmoplegia

Polymyositis (chronic graft vs host) following allogeneic bone marrow transplantation

- ▶ Weakness. Pain can create the appearance of weakness, often with a sudden reduction in effort. Watching a person walking on their toes or heels, hopping, or walking up-stairs is more revealing than just a couch-based assessment.³⁷
- ▶ Myopathic electrophysiology
- ▶ HyperCKaemia (>2 to 3 times)
- ▶ Exercise-induced pain (including a second wind)
- ▶ Hypertrophy or muscle atrophy

Myotonic dystrophy type 2 may present almost exclusively with myalgia, and similarly, Parkinsonism is easily overlooked in this context.

We explain to patients that the chance of diagnosis is low, perhaps 1 in 20 biopsies, and that non-specific abnormalities are common.^{38–41} An excellent article on muscle biopsy remarked, 'If the clinician cannot find something wrong it is highly unlikely that the tests will!'.⁴²

A variety of pathologies may emerge, including metabolic myopathies, congenital myopathies, neurogenic disorders, mitochondrial disorders, myositis and muscular dystrophies.^{41 43}

What is the role of biopsy in patients with exercise-induced muscle pain?

Common causes for exercise-induced myalgia include neurogenic or vascular claudication; amyloid myopathy can rarely cause claudication.⁴⁴

The celebrated 'lactate burn' is well known, being familiar to genuine athletes and also a beloved exhortation roared out by commentators and armchair athletes as the home straight beckons. However, patients with McArdle's disease suffer exercise-induced pain but produce no lactate; lactate probably does not fully deserve its epithet.

This group includes the metabolic myopathies: their clinical features and workup are described elsewhere.²⁶ Remember that the metabolic gene panel is not exhaustive; if the panel is negative but clinical suspicion remains then a muscle biopsy may reveal, for example, a mutation in cytochrome b, the only mtDNA-encoded gene in complex III.⁴⁵

Other exercise-induced muscle phenomena, such as myotonia, often require electrophysiology and genetic tests rather than biopsy. Muscle biopsy has no role in suspected skeletal muscle channelopathy, for instance, and the diagnosis is genetic.

Some other potential indications for a muscle biopsy

Patients with suspected peripheral nerve vasculitis should have combined nerve and muscle biopsy since the chances of positive histology increase from about 50% to 70% compared with a nerve biopsy alone.⁴⁶ A generous biopsy from an asymptomatic muscle may reveal non-caseating granulomas, in a challenging case of possible neurosarcoidosis.⁴⁷ Early skin or muscle biopsy may help in the frequently elusive diagnosis of intravascular lymphoma.⁴⁸

Case 1

A 36-year-old woman said her hands felt stiff in the morning, waking her from sleep. I (RJW) considered carpal tunnel syndrome, but nerve conduction tests were normal. At review, I noticed roughened hyperkeratotic skin on the radial border of her thumbs and on the ulnar border of her index fingers (figures 10). She had a mild proximal weakness that I had overlooked initially. Her serum CK was 2700 IU/L (25–200). The stiffness in her hands reflected a non-erosive arthritis.

She had positive anti-Jo-1 antibodies, one of the myositis-specific anti-aminoacyl transfer RNA synthetase antibodies. She had an antisynthetase syndrome with mechanic's hands, myositis, arthralgia, Raynaud's phenomenon and evidence of pulmonary fibrosis on high-resolution CT scan of the chest.

I did not undertake a muscle biopsy, the diagnosis seemed clear and she improved on corticosteroid and mycophenolate mofetil.

Case 2

A 22-year-old man with mild learning difficulty had experienced several bouts of rhabdomyolysis and myoglobinuria after exercise. For example, his forearms had become swollen and painful the day after activities such as go-kart racing and paint balling.

In his early teens, he had developed a malignant hyperthermia-type reaction after a general anaesthetic for wisdom tooth removal. A muscle biopsy after this had shown a positive in vitro contraction test. He was

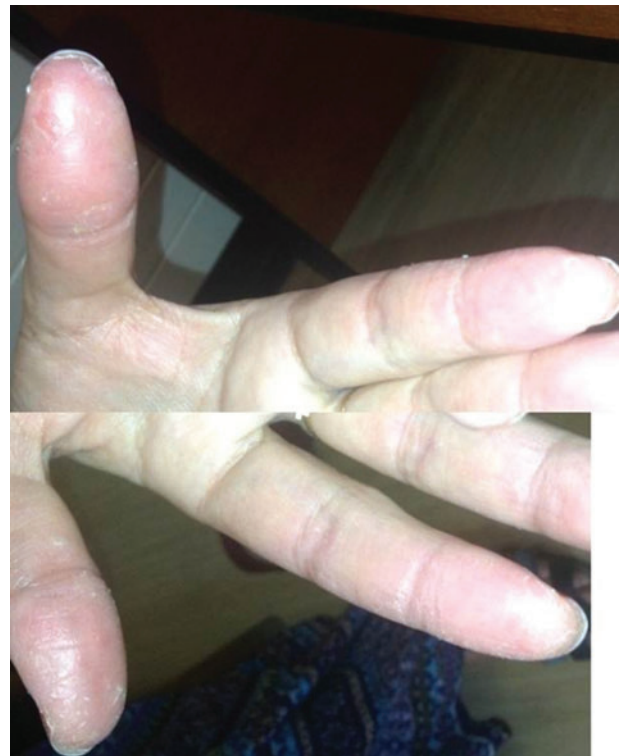


Figure 10 (A and B) Mechanic's hands.

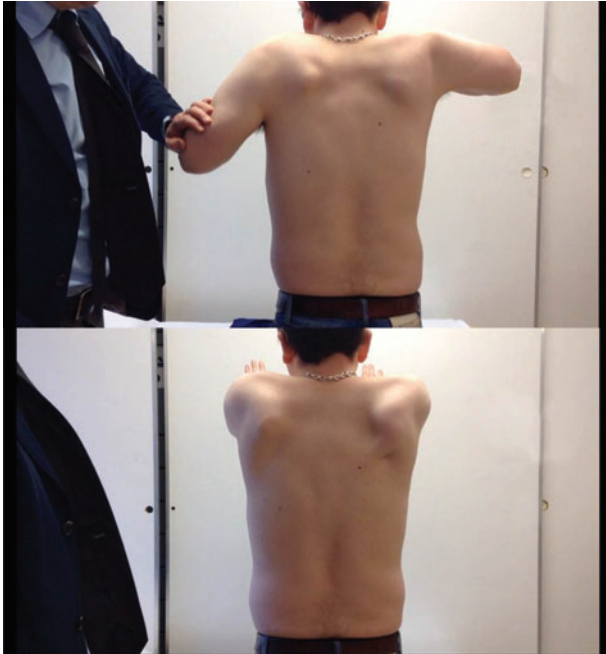

Figure 11 (A and B) Person with Becker muscular dystrophy who has proximal shoulder weakness and scapular winging.

diagnosed with malignant hyperthermia. The biopsy was not analysed further and he had no genetic tests.

We considered a ryanodine mutation, given his malignant hyperthermia and exercise-induced rhabdomyolysis, but he had large calves, winged scapulae and mild limb-girdle pattern weakness (figure 11). His serum CK was about 1500 IU/L (25–200). Further immunohistochemical staining led to the diagnosis of Becker muscular dystrophy.

The practical message is that all muscle biopsies should be analysed methodically; clinicians and pathologists need to discuss each case. The diagnosis may have important implications for family members.

Key points

- ▶ Muscle biopsy remains important in investigating potentially myopathic weakness, although its role differs with the pattern of weakness.
- ▶ For myopathies recognisable at the bedside, a genetic or metabolic test may be the next step.
- ▶ Muscle biopsy may help in myositis, rhabdomyolysis, hyperCKaemia, myalgia and drug-related myopathies, but only in a proportion of cases and after other investigations.
- ▶ Clinicians should communicate early with those undertaking the biopsy and the pathologist, upon whose expertise we rely for interpretation.
- ▶ Having some insights into muscle pathology enriches clinical life and helps us to decipher results for our patients.

Correction notice This article has been corrected since it was published Online First. An author name has been amended.

Acknowledgements We would like to thank Miss Georgia Robinson and Steve Atherton, Medical Illustration Department, Swansea Bay UHB for their considerable help and expertise.

Contributors JW and AB contributed to the design, writing and review of this manuscript.

Funding The authors have not declared a specific grant for this research from any funding agency in the public, commercial or not-for-profit sectors.

Competing interests None declared.

Patient consent for publication Consent obtained directly from patient(s).

Provenance and peer review Commissioned. Externally peer reviewed by Michael Rose, London, UK, and James Holt, Liverpool, UK.

Open access This is an open access article distributed in accordance with the Creative Commons Attribution Non Commercial (CC BY-NC 4.0) license, which permits others to distribute, remix, adapt, build upon this work non-commercially, and license their derivative works on different terms, provided the original work is properly cited, appropriate credit is given, any changes made indicated, and the use is non-commercial. See: <http://creativecommons.org/licenses/by-nc/4.0/>.

FURTHER READING

- Rietveld A, Lim J, de Visser M *et al*. Autoantibody testing in idiopathic inflammatory myopathies. *Pract Neurol* 2019;19:284–94.
- Lilleker JB, Keh YS, Roncaroli F *et al*. Metabolic myopathies: a practical approach. *Pract Neurol* 2018;18:14–26.
- Walters RJ. Muscle diseases: mimics and chameleons. *Pract Neurol* 2014;14:288–98.
- Hilton-Jones D. Statin-related myopathies. *Pract Neurol* 2018;18:97–105.

REFERENCES

- 1 Shukla S, Gultekin SH, Saporta M. Pearls and Oysters: hydroxychloroquine induced toxic myopathy mimics pompe disease: a critical role of genetic test. *Neurology* 2019;92e:742–5.
- 2 Dubowitz VR, Sewry CA, Oldfors A. *Muscle biopsy: a practical approach*. 4th edn. Philadelphia: Saunders, 2013.
- 3 Karpai G, Hilton-Jones D, Bushby B, *et al*. *Disorders of voluntary muscle*. 8th edn. Cambridge, UK: Cambridge University Press, 2010.
- 4 Nass MM, Nass S. Intramitochondrial fibers with DNA characteristics. I. Fixation and electron staining reactions. *J Cell Biol* 1963;19:593–611.
- 5 Walters RJ. Muscle diseases: mimics and chameleons. *Pract Neurol* 2014;14:288–98.
- 6 Khadlikar SV, Patel BA, Lalkaka JA. Making sense of the clinical spectrum of limb girdle muscular dystrophies. *Pract Neurol* 2018;18:201–10.
- 7 Hilton-Jones D, Turner MR. *Oxford textbook of neuromuscular disorders*. UK: Oxford University Press, 2014.
- 8 Renard D. Serum CK as a guide to the diagnosis of muscle disease. *Pract Neurol* 2015;15:121.
- 9 Rubegni A, Malandrini A, Dosi C, *et al*. Next-generation sequencing approach to hyperCKemia. *Neurol Genet* 2019;5:e352.
- 10 Rossor AM, Evans MRB, Reilly MM. A practical approach to the genetic neuropathies. *Pract Neurol* 2015;15:187–98.
- 11 Walters RJ. Contractures and muscle disease. *Pract Neurol* 2016;16:258–63.

- 12 Brady S, Squier W, Hilton-Jones D. Clinical assessment determines the diagnosis of inclusion body myositis independently of pathological features. *J Neurol Neurosurg Psychiatry* 2013;84:1240–6.
- 13 Gorman GS, Schaefer AM, Ng Y, *et al.* Prevalence of nuclear and mitochondrial DNA mutations related to adult mitochondrial disease. *Ann Neurol* 2015;77:752–9.
- 14 Chinnery PF. Could it be mitochondrial? When and how to investigate. *Pract Neurol* 2006;6:90–101.
- 15 Chinnery PF. The mitochondrion and its disorders. *Pract Neurol* 2003;3:100–5.
- 16 Rocha MC, Grady JP, Grunewald A, *et al.* A novel immunofluorescent assay to investigate oxidative phosphorylation deficiency in mitochondrial myopathy: understanding mechanisms an improving diagnosis. *Sci Rep* 2015;15:15037.
- 17 Rahman S, Hanna MG. Diagnosis and therapy in neuromuscular disorders: diagnosis and new treatments in mitochondrial diseases. *J Neurol Neurosurg Psychiatry* 2009;80:943–53.
- 18 Stewart JB, Chinnery PF. The dynamics of mitochondrial DNA heteroplasmy: implications for human health and disease. *Nat Rev Genet* 2015;16:530–42.
- 19 Rahman S, Poulton J, Marchington D, *et al.* Decrease of 3243 A–G mtDNA mutation from blood in MELAS syndrome: a longitudinal study. *Am J Hum Genet* 2001;68:238–40.
- 20 Harding AE. Growing old: the most common mitochondrial disease of all? *Nat Genet* 1992;2:251–2.
- 21 Cauchi M, Marsh E. A practical approach to the patient presenting with dropped head. *Pract Neurol* 2016;16:445–51.
- 22 Rietveld A, Lim J, de Visser M, *et al.* Autoantibody testing in idiopathic inflammatory myopathies. *Pract Neurol* 2019;19:284–94.
- 23 Van De Viekkert J, Maas M, Hoogendijk JE, *et al.* Combining MRI and muscle biopsy improves diagnostic accuracy in subacute-onset idiopathic inflammatory myopathy. *Muscle Nerve* 2015;51:253–8.
- 24 Fernandes PM, Davenport RJ. How to do it: investigate exertional rhabdomyolysis (or not). *Pract Neurol* 2019;19:43–8.
- 25 Scalco RS, Snoeck M, Quinlivan R, *et al.* Exertional rhabdomyolysis: physiological response or manifestation of an underlying myopathy? *BMJ Open Sport Exerc Med* 2016;2:e000151–15.
- 26 Lilleker JB, Keh YS, Roncaroli F, *et al.* Metabolic myopathies: a practical approach. *Pract Neurol* 2018;18:14–26.
- 27 Muldoon S, Deuster P, Voelkel M, *et al.* Exertional heat illness, exertional rhabdomyolysis, and malignant hyperthermia: is there a link? *Curr Sports Med Rep* 2008;7:74–80.
- 28 Nicolau S, Liewluck T, Tracy JA, *et al.* Congenital myopathies in the adult neuromuscular clinic. Diagnostic challenges and pitfalls. *Neurol Genet* 2019;5:e341.
- 29 Chinnery PF, Johnson MA, Taylor RW, *et al.* A novel mitochondrial tRNA phenylalanine mutation presenting with acute rhabdomyolysis. *Ann Neurol* 2004;41:408–10.
- 30 Silvestri NJ, Wolfe GI. Asymptomatic/pauci-symptomatic creatine kinase elevations (hyperckemia). *Muscle Nerve* 2013;47:805–15.
- 31 Kyriakides T, Angelini C, Scafer J, *et al.* EFNS guidelines on the diagnostic approach to pauci or asymptomatic hyperCKemia. *Eur J Neurol* 2010;17:767–73.
- 32 Prella A, Tancredi L, Sciacco M, *et al.* Retrospective study of a large population of patients with asymptomatic or minimally symptomatic raised serum creatine kinase level. *J Neurol* 2002;249:305–11.
- 33 Fernandez C, de Paula AM, Figarella-Branger D, *et al.* Diagnostic evaluation of clinically normal subjects with chronic hyperCKemia. *Neurology* 2006;66:1585–7.
- 34 Hilton-Jones D. Statin-related myopathies. *Pract Neurol* 2018;18:97–105.
- 35 Parker BA, Capizzi JA, Grimaldi AS, *et al.* Effect of statins on skeletal muscle function. *Circulation* 2013;127:96–103.
- 36 Mastaglia FL. Drug induced myopathies. *Pract Neurol* 2006;6:4–13.
- 37 Petty R. Evaluating muscle symptoms. *J Neurol Neurosurg Psychiatry* 2003;74:iii38–42.
- 38 Kyriakides T, Angelini C, Schaefer J, *et al.* EFNS review on the role of muscle biopsy in the investigation of myalgia. *Eur J Neurol* 2013;20:997–1005.
- 39 Kissel JT. Muscle biopsy in patients with myalgia: still a painful decision. *Neurology* 2007;68:170–1.
- 40 Echaniz-Laguna A, Chanson J-B. Electromyography and muscle biopsy in chronic isolated myalgia: a prospective study. *Muscle Nerve* 2016;54:321–6.
- 41 Filosto M, Tonin P, Vattemi G, *et al.* The role of muscle biopsy in investigating isolated muscle pain. *Neurology* 2007;68:181–6.
- 42 Hall G. Muscle biopsy. *Pract Neurol* 2001;1:113–18.
- 43 Te Riele MG, Schreuder TH, van Alfen N, *et al.* The yield of diagnostic work-up of patients presenting with myalgia, exercise intolerance, or fatigue: a prospective observational study. *Neuromuscul Disord* 2017;27:243–50.
- 44 Gertz MA, Kyle RA. Myopathy in primary systemic amyloidosis. *J Neurol Neurosurg Psychiatry* 1996;60:655–60.
- 45 Andreu AL, Hanna MG, Reichmann H, *et al.* Exercise intolerance due to mutations in the cytochrome b gene of mitochondrial DNA. *N Engl J Med* 1999;341:1037–44.
- 46 Collins MP, Mendell JR, Periquet MI, *et al.* Superficial peroneal nerve/peroneus brevis muscle biopsy in vasculitic neuropathy. *Neurology* 2000;55:636–43.
- 47 Joseph FG, Scolding NJ. Sarcoidosis of the nervous system. *Pract Neurol* 2007;7:234–44.
- 48 Tahsili-Fahadan P, Rashidi A, Cimino PJ, *et al.* Neurologic manifestations of intravascular large B–cell lymphoma. *Neurol Clin Pract* 2016;6:55–60.