

# C2 and C3 pain dermatomes in man

Charles E Poletti

## Cephalalgia

Poletti CE. C2 and C3 pain dermatomes in man. *Cephalalgia* 1991;11:155-9. Oslo. ISSN 0333-1024.

This report defines the C2 and C3 pain dermatomes by the distribution of: the hypalgesia clearing after surgical root decompression; the dysaesthesias produced by electrical root stimulation; and the hypalgesia produced by anaesthetic root block. The C2 pain dermatome, so defined, consists of an occipital parietal area 6-8 cm wide, ascending paramedially from the subocciput to the vertex. The C3 pain dermatome is a craniofacial area including the scalp around the ear, the pinna, the lateral cheek over the angle of the jaw, the submental region and the lateral and anterior aspects of the upper neck. These C2 and C3 pain dermatomes do not overlap and are smaller than the C2 and C3 tactile dermatomes described in the literature. • *C2 nerve, C3 nerve, cervical radiculopathy, cervicogenic headache, dermatomes*

*Charles E Poletti, Neurosurgical Pain Service, Massachusetts General Hospital, Boston, MA 02114, USA; Accepted 5 February 1991*

Dermatomes vary as a function of the methods used for their definition. The C2 and C3 dermatomes have been variously defined based on embryonic development (1-3), herpetic eruptions (4), areas of vasodilatation resulting from nerve root stimulation (5), and the areas of tactile sensation remaining after rhizotomies of caudal roots (5). These dermatomes are referred to, respectively, as embryonic, herpetic, vasodilatation and tactile dermatomes. Pain dermatomes, defined by areas of hypalgesia associated with nerve root lesions, have also been described but not for C2 and C3 (6). This study defines the C2 and C3 pain dermatomes in a personal series of 17 patients. Four methods are used: Microsurgical root decompression, rhizotomy, nerve root electrical stimulation (preceding anaesthetic root block), and diagnostic anaesthetic nerve root block.

## Methods

### *Microsurgical root decompression*

The data from six patients presenting with radicular pain and a hypalgesic sensory deficit which cleared completely after microneurosurgical de-compression of the C2 (three patients) and C3 roots (three patients) have been used for this study. The technique for pre- and postoperative testing for cutaneous areas of hypalgesia and analgesia is described below.

### *Rhizotomy*

Two patients underwent a microsurgical unilateral C2 rhizotomy, one intradural and one extra-dural. Preoperatively, neither patient had a cephalic hypalgesic deficit. Postoperatively, hypalgesic or analgesic areas were mapped.

### *Nerve root electrical stimulation*

In seven patients undergoing a diagnostic C2 or C3 nerve root block a 5 mm uninsulated tip 20 gauge Radionics needle electrode was used. Before injecting the xylocaine through this needle to produce the root block the needle electrode was stimulated with a Radionics Stimulator at 50 cps 1 msec duration. The voltage threshold for eliciting any sensation, the threshold for disagreeable sensations and the area to which the dysaesthetic sensations were referred were determined. The threshold for eliciting any sensations was used to position the needle tip as close to the nerve as feasible. Four patients underwent C2 root stimulation. On a different day two of these patients also underwent C3 root stimulation. Three patients underwent only C3 root stimulation, one patient received stimulation of the right and left C3 nerve root on separate days.

### *Anaesthetic nerve root block*

A *C2 nerve root block* was performed in six patients using a method similar to one previously described (7). With the patient lying on his/her side, the needle, inserted posteriorly, is guided to the C2 root and ganglion region using high-resolution fluoroscopy. When the needle tip was close to the nerve root, as determined by electrical stimulation thresholds or mechanically elicited radicular dysaesthesias, 0.4-1.0 ml of 1% xylocaine with epinephrine (adrenaline) was injected. Resulting areas of dense hypalgesia or analgesia were mapped.

A *C3 nerve root block* was performed in eight patients, one bilaterally. With the patient supine the needle was inserted antero-laterally through the C2-3 foramen until the tip was just rostral to the C3 pedicle. After injecting 0.6-1.3 ml 1% xylocaine the resulting areas of dense hypalgesia or analgesia were mapped.

### Mapping areas of cutaneous hypalgesia

Multiple sequential pinpricks applied at right angles to the surface area being tested were used to define cutaneous areas of dense hypalgesia (pinprick perceived as 1-4/10 compared with 10/10 in control areas) or areas of analgesia (inability to discriminate finger tip and pinprick from only finger tip). The transition zone between dense hypalgesia or analgesia and normalgesia was tested and marked at multiple points on the patient's scalp or skin. Using measurements these points were transferred to standard lateral and posterior drawings of the head. These points were connected in each case to delineate the area of sensory loss.

### Results

#### C2 pain dermatome

C2 root decompression in three patients resulted in complete clearing of their preoperative hypalgesic sensory deficit. The least extensive of these deficits is presented in Fig. 1A, the intermediary patient in Fig. 1B and the patient with the most extensive preoperative deficit shown in Fig. 1C. In all three patients the densely hypalgesic area cleared within 20 days postoperatively.

Electrical and mechanical stimulation of the C2 nerve root elicited dysaesthesias confined to the areas subsequently rendered hypalgesic by the anaesthetic nerve root block, except in two patients reporting dysaesthesias in the ipsilateral retro-orbital region.

The extremes of the area rendered densely hypalgesic following C2 anaesthetic nerve root block on the six patients are shown in Fig. 2A, B. The distribution of the analgesia produced in the patient undergoing an extradural C2 rhizotomy is shown in Fig. 2C. AP and lateral X-rays showing the needle tip position for an effective C2 root block is shown in Fig. 3A, B.

#### C3 pain dermatome

C3 root decompression in three patients resulted in complete clearing of the preoperative hypalgesic sensory deficit. The preoperative deficit for each patient is illustrated in Fig. 4A, B, C. These deficits cleared completely postoperatively by 9, 5 and 17 days, respectively.

C3 root electrical and mechanical stimulation elicited dysaesthesias referred most frequently to the area behind the ear under the pinna. Three patients, at suprathreshold stimulation, reported sensations referred to the ear itself, angle of the jaw and along the mandible to the chin. No patient reported dysaesthesias referred to trigeminal regions.

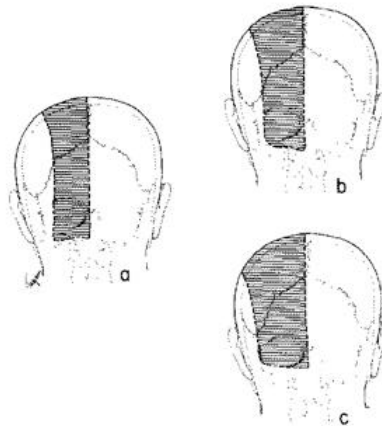


Fig. 1. Hypalgesic areas which cleared after operative C2 root decompression. The least extensive area is shown for a patient in (a) an intermediate size area is shown in (b) and the most extensive preoperative deficit is shown in (c).

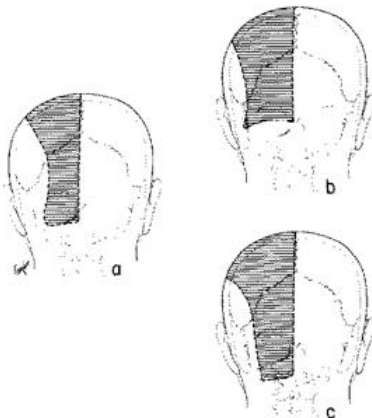


Fig. 2. The range of hypalgesic areas produced by selective C2 anaesthetic root block is shown in (a) and (b); the hypalgesic area produced by an extradural C2 rhizotomy is shown in (c).

The extremes in the size of the area rendered densely hypalgesic by C3 root block in the eight patients are shown in Fig. 5A, C. An intermediary deficit is shown in Fig. 5B. AP and lateral X-rays showing the needle tip position for a C3 root block are shown in Fig. 3C, D.

#### Relation of C2 and C3 pain dermatomes

The C2 area of maximal hypalgesic sensory loss, shown in Figs. 1C, 2B, C, does not overlap with the area of maximal C3 hypalgesic sensory loss, shown

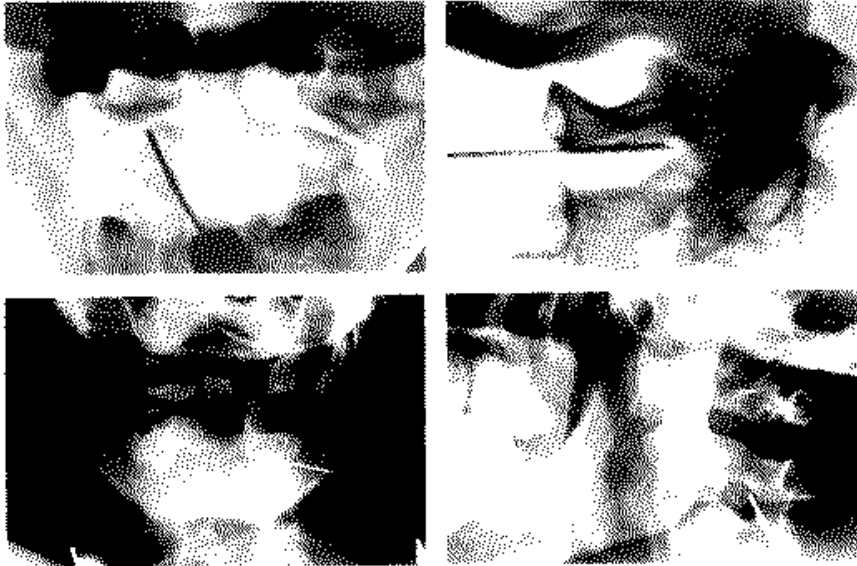


Fig. 3. The needle tip position for a C2 anaesthetic root block is shown in an AP and lateral X-ray, upper left and upper right. The needle tip position for a C3 root block is shown in an AP and lateral X-ray, lower left and lower right.

in Figs. 4B, 4C, 5C, except occasionally for a small area in the suboccipital region. Two patients underwent a C2 block, followed days later, by an ipsilateral C3 block. The C2 and C3 hypalgesic and analgesic areas produced in each patient were within 1 cm in contiguous zones but did not overlap in either patient.

A composite diagram of the C2 and C3 pain dermatomes, resulting from the current methods, is presented in Fig. 6.

#### Discussion

The first estimations of the C2 and C3 dermatomes, by Luciani in 1891 (1), Bolt in 1898 (2) and Edinger in 1904 (3), were based on the migration of embryonic lines of segmental innervation. Herpetic eruptions were used by Head in 1910 (4) to estimate the C3 dermatome. To date, however, virtually all diagrams of the C2 and C3 dermatomes, including those associated with Keegan's diagram of the lower cervical pain dermatomes (6), represent the C2 and C3 tactile dermatomes described by Foerster in 1932 (5). Foerster defined the C2 and C3 dermatomes as "tactile" dermatomes based on the area of remaining sensibility to touch after caudal cervical rhizotomies. The C2 tactile dermatome was delineated after combined rhizotomies of C3, C4 and C5; and the C3 tactile dermatome defined as the additional area of tactile sensibility remaining after combined rhizotomies of C4, C5 and C6 (Fig. 6A).

These C2 and C3 tactile dermatomes differ in their distribution from the C2 and C3 pain dermatomes defined in the current study (Fig. 6). The C2 pain dermatome consists of an occipital parietal area 6-8 cm wide and ascending paramedially from the subocciput to the vertex. Inferiorly the C2 pain dermatome is usually 6 cm wide; superiorly 7-8 cm. It extends anteriorly to a line on the scalp intersecting a coronal plane through the external auditory canal. The C3 pain dermatome is a craniofacial area including the scalp above and behind the ear, the medial and usually most of the lateral surface of the pinna, the lateral cheek over the angle of the jaw, the sub-mental region and the lateral and anterior aspect of the upper neck. In the suboccipital region these C2 and C3 pain dermatomes may overlap in some individuals. These upper cervical pain dermatomes extend precisely to the borders of the dermatomal areas supplied by the first, second and third divisions of the trigeminal nerve, except in the circular area around the external auditory meatus-an area described as innervated by the seventh cranial nerve.

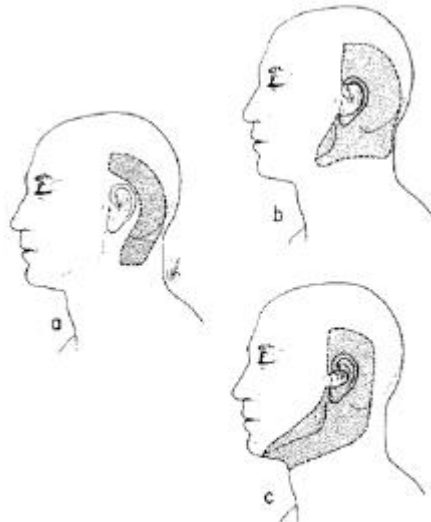


Fig. 4. Hypalgic areas which cleared after operative C3 root decompression. The hypalgic area initially present in a patient is shown in (a); in the same patient a more extensive preoperative deficit, 1.5 months later, is shown in (b). The most extensive preoperative sensory deficit is shown, for another patient, in (c).

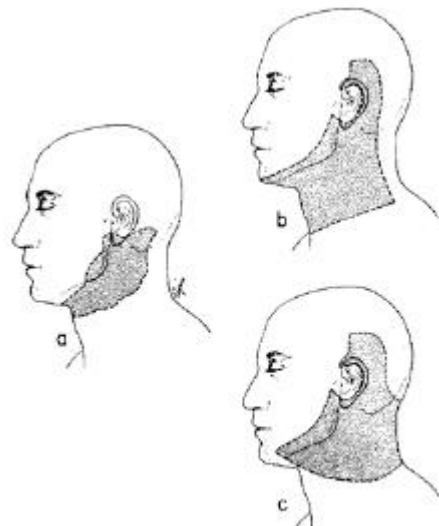


Fig. 5. The range of hypalgic sensory deficits produced by a selective C3 anaesthetic root block is shown, by three patients, in (a), (b) and (c).

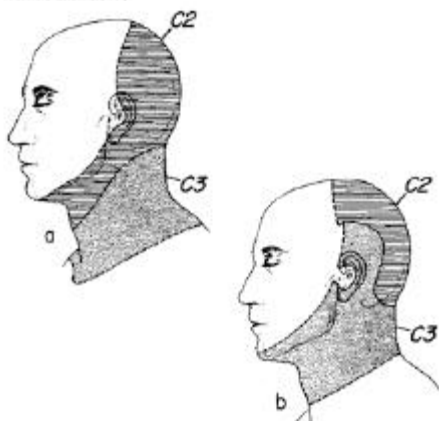


Fig. 6. C2 and C3 dermatomes. The upper figure depicts the C2 and C3 tactile dermatomes as defined by Foerster. The lower figure depicts the C2 and C3 pain dermatomes as defined by the current study.

Using the current methods there has been no evidence of a distinct C1 pain dermatome, consistent with the fact that C1 dorsal root fibres are sparse and rarely present in man.

In conclusion, different syndromes of cephalic pain have been related to upper cervical disease and specifically to the C2 and C3 nerves—most notably by Sjaastad (8, 9), Jansen (10) and others (7, 11-17). The current definition of the C2 and C3 pain dermatomes may assist in the diagnosis of these different syndromes of cervicogenic craniofacial pain.

*Acknowledgements.*—The author expresses his gratitude to Mrs E Tagrin for the medical figures and to Ms J Knight for her secretarial contributions to the final manuscript. The work was supported by NINCDS MGH Pain Program Project Grant PO1 NS23357.

#### References

1. Luciani L. Il cervello: nuovi studi di fisiologia normale e pathologica. Florence: Le Monnier 1891
2. Bolk L. Die Segmentdifferenzierung des menschlichen Rumpfes und seiner Extremitäten. I. Morphol Jahrb 25:465-

543; *ibid.*, 26:91-211; *ibid.*, 27:630-711; *ibid.*, 28:105-46

3. Edinger L. Neue Darstellung der segmentinnervation des menschlichen. Körpers *Zeitschr F Klin Med* 53;1904:52-7
4. Head H. Herpes Zoster. *Allbutt and Roleston's system of medicine*. London: Macmillan 1910;7
5. Foerster O. The dermatomes in man. *Brain* 1932;56:1-38
6. Keegan JJ. Dermatome hypalgesia with posterolateral herniation of lower cervical intervertebral disc. *J Neurosurg* 1947;4: 115-39
7. Bogduk N. Local anesthetic blocks of the second cervical ganglion. A technique with application in occipital headache. *Cephalalgia* 1981;1:41-50
8. Sjaastad O, Saunte C, Hovdahl H, Breivik H, Gronbaek E. "Cervicogenic" headache. An hypothesis. *Cephalalgia* 1983; 3: 249-56
9. Sjaastad O, Fredriksen T, Stolt-Nielsen A. Cervicogenic headache, C2 rhizopathy, and occipital neuralgia: A connection? *Cephalalgia* 1986;6:189-95
10. Jansen J, Markakis E, Rama B, Hildebrandt J. Hemicranial attacks or permanent hemicrania-a sequel of upper cervical root compression. *Cephalalgia* 1989;9:123-30
11. Hunter CR, Mayfield FH. Role of the upper cervical roots in the production of pain in the head. *Am J Surg* 1949;48:743-51
12. Dugan ME, Locke S, Gallagher JR. Occipital neuralgia in adolescents and young adults. *New Engl J Med* 1962;1166-72
13. Maigne R. Signes cliniques des cephalées cervicales: Leur traitement. *Med Hyg* 1981;39:1174-85
14. Poletti CE. Proposed operation for occipital neuralgia: C2 and C3 root decompression. *Neurosurgery* 1983;12:221-4
15. Ehni G, Benner B. Occipital neuralgia and the C1-2 arthrosis syndrome. *J Neurosurg* 1984;61:961-5
16. Bogduk N, Marsland A. On the concept of third occipital headache. *J Neurol Neurosurg Psychiatry* 1986;49:775-80
17. Keith WS. "Whiplash"-injury of the 2nd cervical ganglion and nerve. *Can J Neurol Sci* 1986;13:133-7